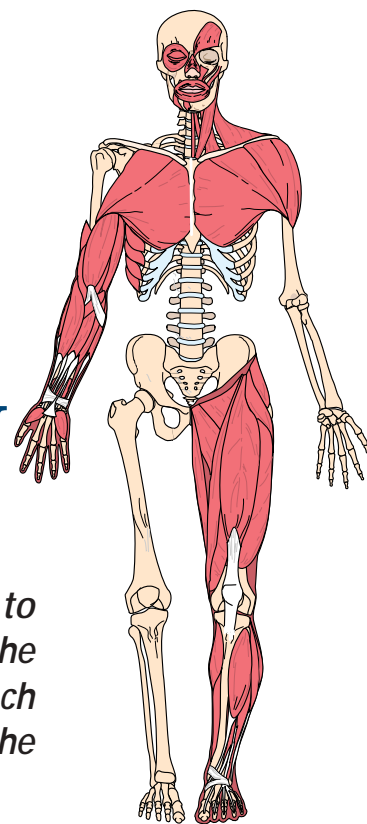

THE SPORTS MEDICINE SPECIALIST'S APPROACH TO THE HIP, PELVIS AND GROIN



This is the fourth article in a sports medicine series intended to review musculoskeletal conditions that commonly appear to the primary physician's attention. Dr. Abdulla's personal approach to history and physical examination is presented to assist in the development of the reader's own techniques.



By Aly S. Abdulla, BSc, MD, LMCC, CCFP(C),
DipSportMed (CASM); and Faiza Abdulla, CDA, executive
director and owner, The Kingsway Health Centre.

This article uses classical vignettes to review the most common hip-, pelvis- and groin-related conditions that present to the primary-care physician's office. This article also will illustrate a systematic approach to the history and physical examination of the hip, pelvis and groin, as was done in previous articles, from the thigh through to the toes.¹⁻³

When this series is completed, we will have created a comprehensive musculoskeletal approach for our readers to modify for their own compendium. This will not be a comprehensive approach to all possible conditions inflicted on the hip, pelvis and groin. There may be some unmentioned entities that may be incorporated.

Anatomy review

The anterior pelvic girdle is composed of two joints: the hip and the pubic symphysis. The posterior pelvis has the sacroiliac joint, which will be discussed in the next article in this series. The hip is a multi-directional ball-in-socket joint, with the femur (ball) (see Case 1) in the acetabulum (socket). The pubic symphysis is the connecting point for both pubic bones (see Case 2). There are a few bony landmarks that will be important for the hip, pelvis, and groin, as follows: the iliac crest (see Case 3), the anterior superior iliac spine (ASIS) (see Case 4) the pubic tubercle and the greater femoral trochanter (see Case 5).⁴⁻⁸

The muscles of the hip are best presented as functional/locational groups and include the following:

- Adductor/medial — gracilis of the pes anserine, adductor longus, brevis, and magnus (see Case 6);
- Flexor/anterior — iliopsoas, sartorius, and rectus femoris of the quadriceps group;
- Abductor/lateral — gluteus medius; and
- Extensor/posterior — gluteus maximus and hamstrings.⁴⁻⁸

Some of the other clinically significant structures of the anterior pelvis and groin are found in the femoral triangle and include the following:

- Superior — the inguinal ligament connects the ASIS and the pubic tubercle, this is the **course** of inguinal hernias which is important in the differential diagnosis;
- Medial — adductor longus connects the pubic symphysis to mid thigh, and;
- Lateral — sartorius connects the ASIS to the site of attachment of the pes anserine.^{1,4-8} Within the femoral triangle lies the lymph nodes, femoral vein, nerve, and artery (medially to laterally).⁴⁻⁸



Dr. Abdulla is the medical director and sports medicine specialist for The Kingsway Health Centre, Toronto, The Family Sports Medicine Consultants and The Healthy Performer in Toronto, Kanata, and Ottawa.

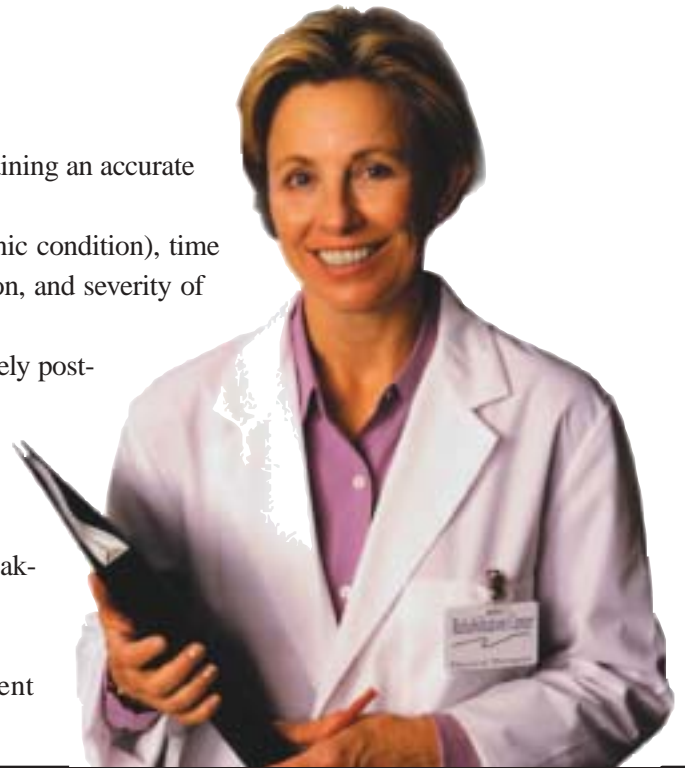


Faiza Abdulla is executive director and owner, The Kingsway Health Centre, Toronto, Ontario.

History

Obtaining a detailed history is tantamount to obtaining an accurate diagnosis.

- Ask about the main complaint (acute or chronic condition), time of onset, method of injury, location, description, and severity of symptoms.
- Ask about the ability to weight-bear immediately post-injury and in the hours afterwards, and the effect on functional activities and gait.
- Ask if there is locking, clicking with pain, or “giving out.”
- Ask about tingling, numbness, swelling, weakness, stiffness, skin or temperature changes.
- Ask about aggravating and alleviating factors.
- It is important to ask what treatments the patient has tried and their effectiveness.



HIP, PELVIS & GROIN

- Ask about previous injuries or similar conditions and their treatments.

As well, it is important to know about pre-existing musculoskeletal abnormalities, especially those involving proximal joints including the lumbar spine and those involving distal joints, such as the thigh, knee, leg, ankle and foot. Finally, questions about other medical conditions (infectious, inflammatory, or congenital), medications, and family history are part of the complete evaluation.¹⁻⁸ In the section Conditions and Their Management (see page 108), the salient history points will be described as classical vignettes.

Physical Examination

Inspection

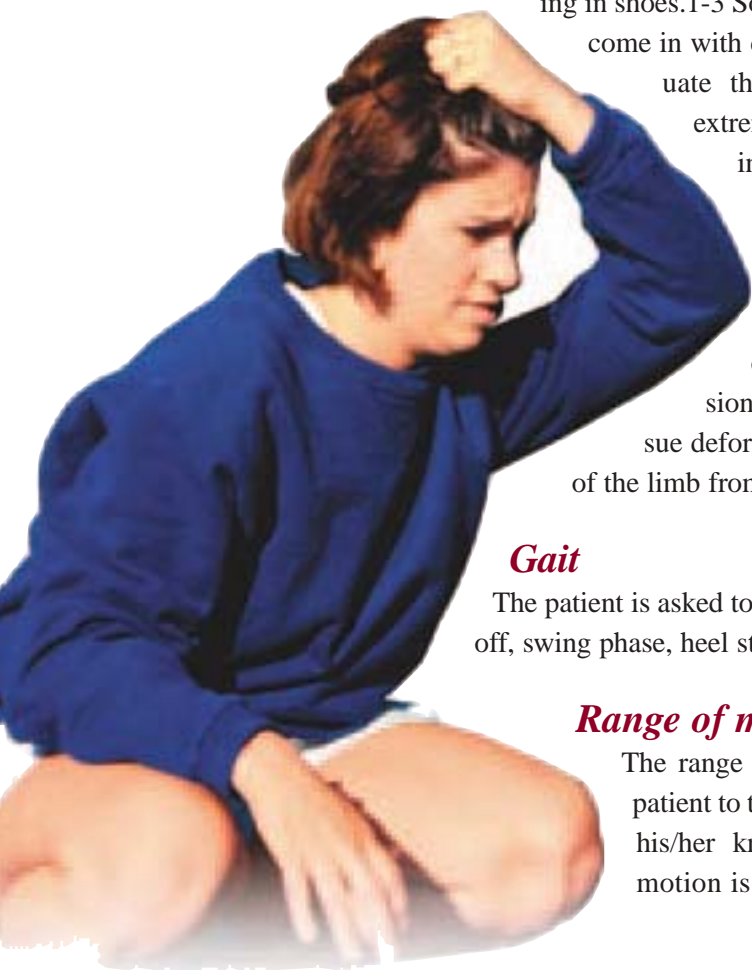
My approach to examination of the hip, pelvis and groin is similar to my examination of all of the lower extremity. It starts with an inspection that takes place while the patient is standing in shoes.¹⁻³ Some patients with hip, pelvis and groin injuries come in with crutches. The first order of business is to evaluate their capacity for weight-bearing, the lower extremity alignment and the gait.¹⁻³ The patient is instructed to remove his/her socks and shoes and to change into shorts. Initially the patient stands facing me and then faces away from me. This allows evaluation of balance, alignment, weight distribution and arches, and the observation of any swelling, masses, joint effusions, bruising and skin changes. Bone or soft tissue deformities also are noted. Remember to inspect all of the limb from hips to feet and to compare both sides.¹⁻³

Gait

The patient is asked to walk and the gait is evaluated for normal push off, swing phase, heel strike, foot flat and mid-stance.⁵

Range of motion

The range of motion is actively assessed by getting the patient to toe raise, heel raise, hop, jump, squat, and bring his/her knee to his/her chest. The passive range of motion is evaluated with manual palpation.





Palpation

Manual palpation begins with the patient standing and facing me. I start on both iliac crests and check for balance or obliquity. I move anteriorly to the iliac tuberosity, down to the ASIS and across the inguinal ligament to the pubic tubercle and pubis symphysis. The greater femoral trochanters are both palpated and their respective heights compared.

The patient is then examined lying supine. I prefer to examine the normal hip, pelvis and groin first, then compare them to the injured side. The greater femoral trochanter and its associated bursa is palpated. The gluteus medius attaches to the greater femoral trochanter. The femoral head lies deeply and medially. The hip is then flexed, abducted, and externally rotated. I start

Case 1:

Hip fracture/femoral head stress fractures/ slipped capital epiphysis

A heavysset, 14-year-old boy started complaining to his mother of a painful knee and said he could no longer attend gym class. The well-meaning mother took him to the doctor, got a negative X-ray report of his knee and promptly sent him back to school. Within days, the boy started limping and complaining even more. By chance, I met this boy when his father presented for a sports medicine consultation.

On examination, there was an obvious limp, limitation in internal rotation, and tenderness in femoral head quadrant compression. Trendelenburg was positive. The suspicion was confirmed by routine X-rays of the hip and the patient was promptly sent for internal fixation. The radiation of pain to the knee in a heavysset adolescent male requires one to consider slipped capital epiphysis.⁴⁻⁹

Case 2:

Osteitis pubis

A 26-year-old first-time mother, who had just weaned her six-month-old baby, presented with a eight-week history of left pubic pain and lower abdominal and thigh pain. She had returned to running recently and her groin and perineum were aching. She was unable to have sex. There was no trouble with the spontaneous vaginal delivery. Her obstetrician insisted that her problem was not gynecological and that she should probably stop running as this made her condition worse. She was unhappy with this advice.

On examination, she had tenderness of the pubic symphysis, the left pubic rami, and pain with adductor stretch. There was decreased range of motion due to discomfort. X-ray and bone scan confirmed a diagnosis related to chronic inflammation. Over the next six months, she exchanged running for swimming, used ice and ultrasound on the region, and focused on adductor stretching and strengthening. We had to inject the region once with cortisone. (Cortisone injections will be the subject of a future article in this series.)^{4-8,10}

Case 3:

Hip pointer, hematoma or contusion

A 59-year-old lawyer and seniors' hockey player presented with a very tender and bruised right hip. The night before, he had crashed into the boards and onto the ice while trying to dig for the puck. There was no discomfort until he got home and noticed that the area was swelling up. He iced the contusion and took some ibuprofen, but as the day progressed he found it increasingly difficult stand up straight. On examination, there was exquisite tenderness and florid bruising at the anterior iliac crest. There was a palpable fluctuant swelling consistent with a hematoma. X-rays ruled out fractures. The patient winced with an oblique sit-up. In an effort to hasten recovery in this eager individual, the hematoma was aspirated and injected with cortisone and a pressure bandage was applied. Then, the standard protocol of rest, ice and anti-inflammatories was followed. Within a short time, the patient was back in the game and discharged with a regimen of gluteal and abdominal strengthening.^{4-8,11}

Case 4:

Apophysitis

A very active 15-year-old boy complained of chronic groin pain. He played hockey, basketball and football. He was involved in track and skiing. Over the last year, his left groin had started aching after his activities. Sometimes it would be sore at night and, unless he took acetaminophen, would prevent him from sleeping. There was no acute trauma and he worked diligently to stretch and strengthen his muscles.

On examination, there was well-localized tenderness of his ASIS and anterior inferior iliac spine (AIIIs), which was the origin of the sartorius and rectus femoris, respectively. There was pain with passive stretch of both of these muscles and symptoms were reproduced with muscle resistance. There was no weakness. X-rays ruled out an avulsion injury. This confirmed chronic irritation of the secondary ossification centres or apophysis, similar to Osgood-Schlatter disease (OSD).^{1,12} He reluctantly consented to limited weight bearing with crutches for two weeks. We added ice and anti-inflammatories. In due course, a range-of-motion program progressed to a graduated stretching and strengthening protocol.^{4-8,12} Within six weeks he was back to winning most valuable player honours.

Case 5: **Trochanteric bursitis**

A 37-year-old, long-distance runner presented with a month-long history of a fairly well-localized discomfort of her right trochanteric bursa. This discomfort worsened when the patient lay on it and after long runs. The pain radiated into the lateral thigh with running. The patient sometimes heard and felt a snapping sensation in her right hip, which also caused her symptoms to worsen. There was no history of trauma. She had tried to correct the condition using ice and a new pair of shoes. This helped only mildly. She had noticed that her problem worsened when she ran cross-country on a cambered road.

On examination, the patient had fairly wide hips, genu valgum, and pes planus. There was no leg-length discrepancy. There was tenderness upon palpation of her right femoral trochanteric bursa. She responded quickly to cortisone injection followed by physical therapy. For future prevention, we discussed appropriate orthotics, precautions against overuse and fatigue, appropriate warm-up and stretching, and attention to running surface.⁴⁻⁸

Case 6: **Abductor strains and avulsion fractures**

A 42-year-old equestrian athlete complained of a chronic groin pull that had been aggravated recently when her horse cut to close to an obstacle and her right leg was externally rotated. She has dealt with this problem on and off for years, but it recently had become extremely painful.

The patient arrived at my office on crutches and could not bear weight on the affected leg. On examination, there was extreme point tenderness over the adductor tubercle. Pain was accentuated with minimal passive abduction of the hip. There was significant ecchymosis, spasm, and swelling. There was some concern about a palpable defect. X-ray did not show an avulsion fracture and ultrasound showed significant swelling and hypoechogenicity without confirming a complete rupture. She responded poorly to rest, ice, compression, anti-inflammatories and ultrasound. Eventually a transverse relaxation time (T2) weighted magnetic resonance imaging (MRI) confirmed a complete rupture.

By our estimation, conservative management was failing and she was referred to surgery. After more than eight weeks of medical management, she was finally able to walk normally. The question of her return to competitive horseback riding is still unanswered.^{4-8, 13}

with the pubic symphysis and the adductor muscle group, the inguinal ligament to rule out hernias, the ASIS and its sartorius insertion, and then the femoral head which, sits deep to the femoral triangle.⁴⁻⁸ (The posterior aspect of the hip and lumbar spine will be the subject of the next article in this series, in the April issue).

Neurovascular

The femoral artery, vein, and nerve are all located in the femoral triangle. The anterior thigh (L1-3/anterior femoral cutaneous), the lateral thigh (L2-3/lateral femoral cutaneous), medial knee to the medial malleolus (L4/saphenous), the lateral knee to the first toe medial edge (L5/superficial peroneal), and the posterior thigh (S2/posterior femoral cutaneous) are tested for pinprick. The hip extensors, flexors, abductors, and adductors are tested for muscle strength. The knee reflex (L4), the Achilles' reflex (S1), and Babinski (upper motor nerve) are tested.⁴⁻⁸

Special tests

The special tests include, if indicated, the following:

- *Trendelenburg*. This measures the normal function of the gluteus medius. While standing behind the patient, the physician asks him/her to stand on one leg. Normally, the gluteus medius on the supported side contracts and prevents the unsupported side from dropping below level. If the unsupported side drops, the patient is Trendelenburg positive.⁵
- *Leg-length discrepancy*. This can be either true or apparent. True leg-length discrepancy is determined by finding an inconsistency between sides by measuring from the ASIS to the medial malleolus (two fixed bony sites). An apparent leg-length discrepancy is determined by finding an inconsistency between sides by measuring from the umbilicus to the medial malleolus (a nonfixed to a fixed site, usually related to pelvic obliquity).⁵

- *Femoral head quadrant compression.* In this test, the hip is moved passively by the examiner throughout its range of motion and challenged with compression at each quadrant of the femoralacetabular articulation. This is an attempt to determine the wear of the ball and socket joint.

Summary

Injuries of the hip, pelvis and groin involve problems similar to those found in the rest of the body. They can be confusing, however, due to complicated anatomy in a small area. The above classical vignettes illustrate some of the common conditions that present to the primary -care physician's office. In an effort to simplify and not confuse, the terminology and nomenclature was maintained throughout article. Not all possible conditions were included, due to space restrictions.

References

1. Abdulla AS, Abdulla F: The sports medicine specialist's approach to knee and thigh. *The Canadian Journal of Diagnosis* 2002; 19(2):83-91.
2. Abdulla AS, Abdulla F: The sports medicine specialist's approach to leg and ankle. *The Canadian Journal of Diagnosis* 2001; 18(11):75-83.
3. Abdulla AS, Abdulla F: The sports medicine specialist's approach to feet and toes. *The Canadian Journal of Diagnosis* 2001; 18(10):123-32.
4. Mellion MB (ed.): *Office Sports Medicine*. Second edition. Philadelphia, 1996, Hanley & Belfus, p. 367.
5. Hoppenfeld S: *Physical examination of the spine and extremities*. East Norwalk, CT, Appleton & Lange, 1976, pp. 143-69.
6. Roy S, Irvin R: *Sports Medicine. Prevention, Evaluation, Management, and Rehabilitation*. Englewood Cliffs, NJ, Prentice-Hall, 1983, pp. 282-7, 428-9.
7. Snell RS: *Clinical Anatomy for Medical Students*. Third edition. Boston, 1986, Little Brown & Company, pp. 553-692.
8. Garrett WE, Speer KP, Kirkendall DT (eds.): *Principles and Practice of Orthopaedic Sports Medicine*. Philadelphia, Lippincott Williams & Wilkins, 2000, pp. 215-611.
9. Paletta GA, Andrich JT: Injuries about the hip and pelvis in the young athlete. *Clin Sports Med* 1995; 14:591-628.
10. Cochrane GM: Osteitis pubis in athletes. *Br J Sports Med* 1971; 5:233-5.
11. Fu FH, Stone DA: *Sports Injuries: Mechanisms, Prevention, and Treatment*. Baltimore, Williams & Wilkins, 1994, p. 442.
12. Peck DM: Apophyseal injuries in the young athlete. *Am Fam Phys* 1995; 51:1891-5.
13. Karlsson J, Sward L, Kalebo P, et al: Chronic groin injuries in athletes, recommendations for treatment and rehabilitation. *Sports Med* 1994; 17:141-8.