

ECG of the Month



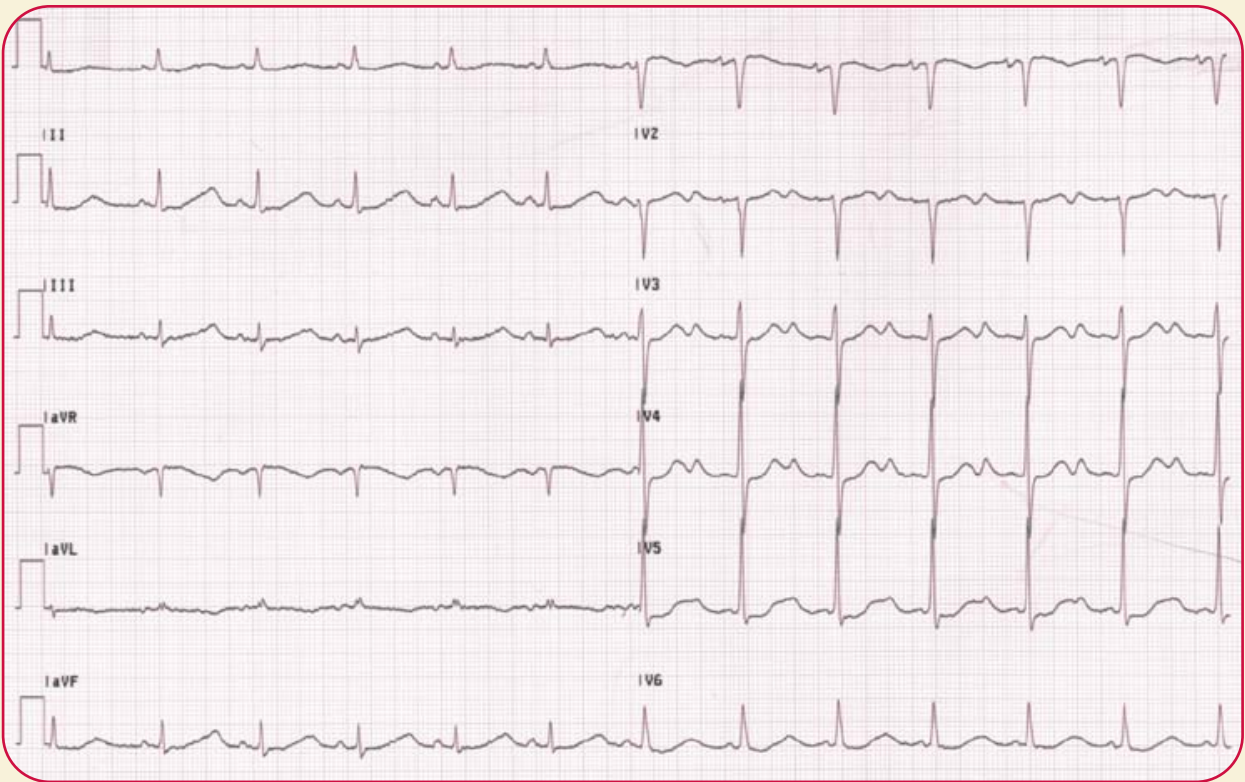
By Martin S. Green, MD, FRCPC

University of
Ottawa Heart Institute

K-Light

A 70-year-old woman presents with weakness. She had been on blood pressure pills. Her ECG is shown below.

What is the diagnosis?






ECG of the Month

University of
Ottawa Heart Institute

This Month's ECG Diagnosis

This ECG shows sinus rhythm at a rate of about 72 beats/minute. Of note, there is normal conduction. The QRS is normal. There are marked abnormalities of repolarization. There is a giant U wave which merges with the T wave so that in leads II and aVF and lead V6, it appears to be a very long QT interval. In the mid-precordial leads, however, one can see that the U wave is in fact larger than the T wave (best seen in lead V5) and that the QT interval is not so much prolonged as a T wave merging with a gigantic U wave.

The presence of gigantic U waves, especially when they are larger than the low flat T wave, is strongly suggestive of a metabolic abnormality, such as hypokalemia. In this particular case, the patient had been on long-term diuretic therapy and presented to the emergency room with potassium of 1.8 mmol/L. The patient had potassium supplementation and discontinuation of the diuretic therapy following which, the ECG returned to normal. 

www.stacomcommunications.com

Back Forward Reload Home Search Images Print Security Shop Stop

Location: www.stacomcommunications.com

WE'RE ON-LINE

The Canadian Journal Of
CME
Continuing Medical Education
Queen's University

40 The Constant Urges to Get The Pressure Right
41 Picking the Perfect Pill: Choosing Oral Contraceptives
42 How Can We Fight Bacteria?
43 What's Old is New
44 What's New
45 How Do We Investigate Progress?
46 Caring for the Kid

The Canadian Journal of
Diagnosis

81 The Limiting Factor: Hypoglycemia & Diabetes
82 What's New in Dermatology?
83 A Pain in The Ankle: How to Assess
84 "What Happened?" Old Cases?
85 Case Report
86 Don't Forget the Patient's Family
87 "Can You Hear My Heart?"
88 New Chapter: Win a Prize!

le clinicien

34 La fibromyalgie: De doute aux découvertes
35 Articles
36 Quels sont les signes de l'hypertension résistante chronique?
37 Attention, une étrange entouffée!
38 Comment préparer un casier?
39 Substitutions
40 Changement de statut clinique
41 Les médicaments dans le traitement de l'asthme
42 Qui de nous dans le traitement de la BPCO?
43 Commentaires: un cas de camera numérique

Cardiology
The Postgraduate Journal

33 KEEPING UP THE PACE: Atrial Fibrillation in Clinical Practice
34 SINKING ON THE ATTACK: Atrial Fibrillation in the Emergency Room
35 Heart Disease in Women: A Look at the Latest Evidence
36 Health Care Quality Improvement
37 Evidence-Based Medicine: A Practical Approach
38 The Global Burden of Disease
39 Frequently Asked Questions: New!

www.stacomcommunications.com