Case 1

Uncomfortable Lesions

Copyright© Not for Sale or Commercial Distribution
Unauthorised use prohibited. Authorised users can download, display, view and print a single copy for personal use

A 17-year-old male has these lesions on both arms and similar lesions on the trunk. They are somewhat uncomfortable.

Questions

1. What is your diagnosis?
2. What is the importance of these lesions in this location?
3. How would you manage this condition?

Answers

1. Acne vulgaris
2. It signifies a more aggressive form of acne, which requires oral systemic therapy rather than topical therapy.
3. Consider prescribing oral antibiotics in the tetracycline family along with topical therapy and/or consider isotretinoin. In females, the oral contraceptive pill and spironolactone are options as well.

Provided by: Dr. Benjamin Barankin

Share your photos and diagnoses with us!

Do you have a photo diagnosis? Send us your photo and a brief text explaining the presentation of the illness, your diagnosis and treatment and receive $25 per item if it is published.

The Canadian Journal of Diagnosis
6500 Trans-Canada Highway, Suite 310
Pointe-Claire, Québec H9R 0A5

Email: diagnosis@sta.ca
Fax: (888) 695-8554

Case 2

Pain and Swelling in the Periorbital Area

A three-year-old boy presents with pain and swelling in the right periorbital area. On physical examination, the child is afebrile. The right periorbital area is red, hot, and tender. The right pupil is normal in size and reacts to light. His vision and eye movements are normal.

Questions

1. What is the diagnosis?
2. What is the significance?
3. What is the treatment?

Answers

1. Preseptal cellulitis (periorbital cellulitis)
2. Preseptal cellulitis refers to an infection of the eyelid and periorbital tissue without any involvement of the orbit or other ocular structure. The condition can be caused by local trauma, an infected wound, acute dacryocystitis, an upper respiratory tract infection, or sinusitis. The common causative organisms include *Staphylococcus aureus*, *Haemophilus influenzae*, *Streptococcus pneumoniae*, other *Streptococci*, and anaerobes. The infection is usually prevented from spreading to the globe by the orbital septum. Preseptal cellulitis has to be differentiated from orbital cellulitis. The latter usually presents with proptosis, decreased vision, and decreased mobility of the eyes in addition to evidence of inflammation. When the diagnosis is in doubt, CT can be used to distinguish preseptal cellulitis from orbital cellulitis.
3. Oral clindamycin is the drug of choice, because it is effective against most strains of community-acquired, methicillin-resistant *Staphylococcus aureus* and other causative organisms.

Provided by: Dr. Alexander K.C. Leung and Dr. Alex H.C. Wong

Case 3

Provided by: Dr. Francesca Cheung

Annular, Scaly Plaques

A 48-year-old male developed pruritic, annular, and scaly plaques on the legs. He was prescribed mometasone for treatment of nummular dermatitis, but he did not find any improvement after one week.

Questions

1. What is the diagnosis?
2. What are the investigations?
3. What is the treatment?

Answers

1. Tinea corporis
2. Mycologic investigations, including direct microscopic examination and culturing, are helpful. Surface scrapings should be obtained from the border of the lesion where more fungal elements and inflammatory reactions are present.
3. Topical antifungal agents, such as ciclopirox and terbinafine, are appropriate.

Case 4

Figure 1: Pre-procedure

Figure 2: Post-operative day 1

Large Lesion on the Forearm

A 91-year-old female with advanced Alzheimer's dementia presents with a several month history of a progressively enlarging, tender lesion on the volar aspect of her right forearm. The lesion bleeds easily and measures 8 cm by 3 cm. A malodorous, purulent discharge is present, which is swabbed; *Staphylococcus aureus* is found on the culture results, and the patient is treated with a course of cloxacillin. The lesion is at high risk of enlarging further, experiencing recurrent infection, and causing continued pain.

Questions

1. What is your diagnosis?
2. What is your differential diagnosis?
3. How can this lesion be managed?

Answers

1. Invasive squamous cell carcinoma (SCC) is a malignant tumour of keratinizing squamous cells in the epidermis that has infiltrated the dermis layer. Invasive SCC usually develops from SCC *in situ*, which itself is often a progression from precancerous lesions like actinic keratosis. Risk factors in developing invasive SCC include presence of precursor lesions, fair skin, ultraviolet radiation exposure, immunosuppression, exposure to ionizing radiation or environmental toxins (*i.e.,* arsenic, tar), and human papillomavirus infection.
2. The differential diagnosis should include basal cell carcinoma, amelanotic melanoma, prurigo nodularis, and pyoderma gangrenosum.
3. Invasive SCC is generally managed with surgical excision, taking into account the lesion size, extent, and location. A variety of techniques for closure can be used, including flaps and grafts. Mohs micrographic surgery can be considered for tumours in cosmetically sensitive areas like the face. In this patient, a surgical excision was undertaken in close consultation with her power of attorney for palliation purposes. Her wound was left to heal by secondary intention over the course of two months.

Provided by: Dr. Alireza Karimi Pour and Dr. Karen Choi

Case 5

Itchy, Red Hands

A 34-year-old woman who recently had her first baby presents with discomfort and itching on her hands of two-months duration.

Questions

1. What is your diagnosis?
2. What are the different types of this rash?
3. How would you manage this condition?

Answers

1. Hand dermatitis (or eczema) or "new mother eczema"
2. Irritant contact dermatitis (*e.g.*, too much washing, not enough moisturizing), allergic contact dermatitis (*e.g.*, allergic contact to nickel), dyshidrotic eczema, and atopic eczema are all types of the rash.
3. Instruct the patient to minimize hand washing, wear gloves when washing dishes, moisturize with a thick cream immediately after washing hands, and increase home humidity in wintertime. Consider a barrier cream (OTC) and use of a mild to mid potency topical steroid, depending on the degree of pruritus.

Provided by: Dr. Benjamin Barankin

Case 6

Red Patches in the Occipital Area

A two-month-old infant presents with red patches in the occipital area and the nape of the neck. The lesions have been present since birth. The colour deepens with crying.

Questions

1. What is the diagnosis?
2. What is the significance?
3. What is the treatment?

Answers

1. Salmon patches.
2. Salmon patches, also known as nevus simplex, are the most common vascular lesions in infancy. In the Caucasian population, salmon patches are present in approximately 44% of all neonates. They are less common in dark-skinned neonates. Both sexes are equally affected. Clinically, salmon patches are scarlet to pink, flat, can be totally blanched, and usually deepen in colour with vigorous activity, crying, straining with defecation, breath-holding, or changes in ambient temperature. In white infants, they are usually bright red or pink and are darker in Oriental or black infants. The lesions are most commonly found on the nape of the neck and occipital area, followed by the glabella and eyelids. Salmon patches are usually symmetric, with lesions on both eyelids or on both sides of the midline. Colloquially, the lesions on the forehead and eyelids are known as "angel's kisses" and the ones in the occipital area as "stork beak marks" or "stork bite marks." Salmon patches are generally not associated with extracutaneous anomalies. However, prominent lesions in the glabella may be associated with Beckwith-Wiedemann syndrome, fetal alcohol syndrome, and Nova syndrome.
3. Treatment consists of providing reassurance to the parents that the lesion will disappear or significantly regress with time.

Provided by: Dr. Alexander K.C. Leung and Dr. Andrew S. Wong

Case 7

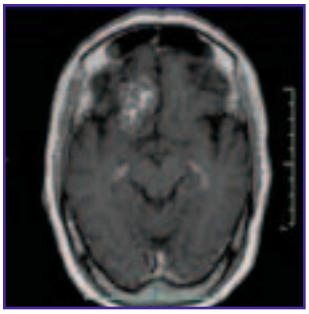

Loss of Consciousness

This is a 67-year-old, right-handed female with a history of multiple episodes of loss of consciousness with shaking of both sides of her body lasting for at least a few minutes. In some of the episodes, she had incontinence of the bladder and tongue biting as well. She had no recollection of the episodes upon regaining consciousness.

Questions

1. What does this image show?
2. What is your diagnosis?
3. How would you manage this case?

Answers

1. This is an axial view of T1 weighted MRI of the brain, with contrast showing a large right frontal lobe lesion with enhancement consistent with the cavernous vascular malformation.
2. This patient had generalized seizures due to cavernous vascular malformation in the right frontal lobe of the brain.
3. This patient should be started on phenytoin, and neurosurgical consultations should be requested for further management of cavernous vascular malformation.

Provided by: Dr. Abdul Qayyum Rana, Dr. Iftikhar Haq, and Mr. Ishraq Siddiqui

Case 8

Figure 1: Herald patch

Erythematous Eruption

A 27-year-old, otherwise healthy, male presents with a one-and-a-half week history of a scaly and mildly pruritic erythematous eruption on the anterior and posterior aspects of his trunk and the proximal aspects of his arms and legs. He remembers the initial appearance of a single lesion on his abdomen. He also notes that he had a recent upper respiratory tract infection just prior to the eruption of this rash.

Questions

1. What is your diagnosis?
2. What are the characteristics of this skin disease?
3. How might you manage his condition?

Figure 2: Christmas tree pattern (anterior chest and abdomen)

Answers

1. Pityriasis rosea.
2. A primary lesion called the herald patch is often noted as the initial lesion. The herald patch is a single, oval-shaped plaque that is usually described as salmon-coloured and often measures 2 to 5 cm in diameter. Development of the generalized rash, consisting of multiple similar-appearing lesions, occurs one to two weeks after the herald patch appears and forms into a Christmas tree-like distribution. The lesions are mostly present on the trunk and the proximal aspects of the extremities, but lesions are rarely present on the face. Pityriasis rosea can be preceded by a viral prodrome and is thought to be associated with the reactivation of human herpesvirus (HHV)-7 or HHV-6.
3. Reassurance should be given to the patient that this is a harmless and noncontagious rash. Spontaneous remission is expected in between 4 and 10 weeks, but the rash can last up to 5 months. The rash is not expected to recur. Mid-potency topical steroid therapy can be used twice a day for control of any associated pruritus. Ultraviolet therapy could also be considered to speed up the resolution of the eruption.

Provided by: Dr. Pita Tingey and Dr. Karen Choi

Case 9

Growing Scalp Lesion

A 67-year-old male presents with this rapidly growing, slightly sensitive lesion on his scalp.

Questions

1. What is your diagnosis?
2. What are the characteristic features of this lesion?
3. How might you manage this patient?

Answers

1. Keratoacanthoma, a low-grade malignancy (considered now to be a variant of squamous cell carcinoma)
2. It is characteristically a rapidly-growing nodule, "volcano-like" lesion with central crusting or keratin plug. In many cases it can resolve on its own after many months, but it is typically treated before that.
3. Excision is the most common treatment. Less commonly, intralesional methotrexate is used. Systemic retinoids are used in the presence of multiple lesions.

Provided by: Dr. Benjamin Barankin

Case 10

Papules on the Trunk

A five-year-old boy presents with a unilateral eruption of papules on his left trunk. The rash is nonpruritic and extends from the upper part of his left arm down to his thorax. The patient experiences no prodromal symptoms. He has not recently received any vaccination or medication. The patient is otherwise healthy.

Questions

1. What is the diagnosis?
2. What is the significance?
3. What is the treatment?

Answers

1. Unilateral laterothoracic exanthem (ULE)
2. ULE, also known as asymmetric periflexural exanthem of childhood, is a papular eruption that tends to start in one axilla then spreads up into the upper arm and down the thorax. The rash can spread centrifugally and, rarely, become bilateral. In addition, eczematization may develop over time. About half of patients with ULE develop pruritus, and about 75% of cases have prodromal symptoms, including rhinitis, mild fever, and diarrhea, suggesting a relationship with viral infection. The exact cause of ULE, however, is unknown. Typically, ULE occurs in children between eight-months- and five-years-of-age during winter and spring, though adults may also be affected. Girls are affected more often than boys. The differential diagnosis includes nonspecific viral exanthems, Gianotti-Crosti syndrome, contact dermatitis, eczema, drug-related eruptions, scarlet fever, miliaria, fungal infections, scabies, and atypical pityriasis rosea. Diagnosis is usually clinical.
3. ULE is self-limiting and will resolve in three to six weeks with no treatment. If pruritus is present, emollients and mild topical steroids may be used. Dx

Provided by: Dr. Andrew S. Wong, Dr. Alexander K.C. Leung, and Dr. Stewart Adams