Illustrated quizzes on problems seen in everyday practice

Case 1

Erythematous Plaque

Copyright© Not for Sale or Commercial Distribution
Unauthorised use prohibited. Authorised users can download, display, view and print a single copy for personal use

A 59-year-old male presents for a skin examination, and an asymptomatic erythematous plaque is noted in the retroauricular region.

Questions

1. What is your diagnosis?
2. What is believed to be the etiology of this lesion?
3. How would you treat this lesion?

Answers

1. Bowen's disease (squamous cell carcinoma in situ)
2. Chronic sun exposure
3. Aggressive liquid nitrogen therapy can be tried, as can topical therapy with imiquimod or 5-fluorouracil. Electrodesiccation and curettage or simple excision are other options.

Provided by: Dr. Benjamin Barankin

Share your photos and diagnoses with us!

Do you have a photo diagnosis? Send us your photo and a brief text explaining the presentation of the illness, your diagnosis and treatment and receive $25 per item if it is published.

The Canadian Journal of Diagnosis
6500 Trans-Canada Highway, Suite 310
Pointe-Claire, Québec H9R 0A5

Email: diagnosis@sta.ca
Fax: (888) 695-8554

Case 2

Pustular Eruption

A three-week-old baby boy presents with a pustular eruption on his cheeks and nose. He is otherwise healthy. The pregnancy and delivery were uneventful.

Questions

1. What is the diagnosis?
2. What is the etiology?
3. What is the treatment?

Answers

1. Neonatal cephalic pustulosis
2. The condition may be due to the increased sensitivity of the infant's sebaceous glands to maternal hormones during pregnancy. Some clinicians believe the condition is secondary to malassezia colonization, but the significance of the role of yeast is unclear.
3. Neonatal cephalic pustulosis clears within a few weeks of symptom onset without treatment.

Provided by: Dr. Francesca Cheung

Case 3

Pink Nodules on Trunk

A 67-year-old female complains of pinkish, painless nodules on the trunk and abdomen; some have become pedunculated. She also has a few brownish macules on her body that first appeared in childhood, while the pink nodules first appeared during her teens. She has mild hypertension. Her family history is noncontributory.

Questions

1. What is the diagnosis?
2. What is the significance?
3. What are the complications?
4. What is the management?

Answers

1. Neurofibromatosis
2. Two forms of neurofibromatosis appear to exist: classical von Recklinghausen's neurofibromatosis (NF1) and central or acoustic neurofibromatosis (NF2). Von Recklinghausen's neurofibromatosis (NF1) is relatively common, affecting about 1 in 5,000. Both types may have café-au-lait macules and neurofibromas, but only the central type has bilateral or unilateral acoustic neuromas. Another feature present in classical NF1, but not present in the central or acoustic type, is Lisch nodules (pigmented hamartomas in the iris), which occur in 94% of patients over 60-years-of-age. The disease shows autosomal dominant inheritance; although it is one of the most common mutations in humans, at least half of the cases represent new mutations. The NF1 gene has been mapped to chromosome 17, and the NF2 is on chromosome 22.
3. Complications develop in about 25% of cases and include hypertension, epilepsy, learning difficulties, scoliosis or bowing of the tibia and fibula, sarcomatous change in neurofibroma (in 1.5 to 15% of cases), and benign tumours of the nervous system, optic gliomas, acoustic neuromas, plexiform neurofibromas, and spinal neurofibromas may develop.
4. Once the diagnosis has been made, genetic counselling and the exclusion of any complicating factors are important.

Provided by: Dr. Jerzy K. Pawlak and Dr. R.Ramgoolam

Case 4

Yellow Discharge

A 27-year-old man presents with a yellow discharge from the right eye of two days' duration. The right eye is also sticky and red. There is no concurrent upper respiratory infection.

Questions

1. What is the diagnosis?
2. What is the significance?
3. What is the treatment?

Answers

1. Bacterial conjunctivitis
2. Bacterial conjunctivitis accounts for approximately 1% of consultations seen by primary care physicians. The most common causative organisms are *Staphylococcus aureus*, *Haemophilus influenzae*, and *Streptococcus pneumoniae*, followed by *Moraxella catarrhalis*. *Staphylococcus aureus* is common in adults, while the other organisms are common in children. Acute bacterial conjunctivitis typically begins unilaterally with a "foreign body," burning, or stinging sensation in the eye and eye crusting on awakening. A purulent ocular discharge is common. The conjunctiva is injected and hyperemic. Within one to two days, the other eye may also get involved. Ocular pain, ocular pruritus, and photophobia are uncommon. Visual acuity is usually unimpaired. Viral conjunctivitis is usually bilateral at outset and is frequently associated with an upper respiratory tract infection. Chemosis strongly suggests allergic conjunctivitis. Chemosis may also be seen in herpes simplex viral conjunctivitis and chlamydial conjunctivitis.
3. Although most cases of bacterial conjunctivitis are self-limited, prompt and appropriate antimicrobial treatment accelerates resolution, enhances eradication of causative organisms, reduces person-to-person transmission, and reduces complications. Since routine culturing of eye swabs is impracticable, empiric treatment with a broad spectrum antibiotic (*e.g.*, polymyxin/trimethoprim ophthalmic drops) seems appropriate in patients with presumed bacterial conjunctivitis.

Provided by: Dr. Alexander K.C. Leung

Case 5

Worsening Facial Lesion

An 11-year-old male has a six week history of a pruritic and erythematous plaque on the right cheek. The symptoms seem to have worsened and have become more prominent since a 1% hydrocortisone cream and a mometasone cream were started four weeks ago.

Questions

1. What is the diagnosis?
2. What are the investigations?
3. What is the treatment?

Answers

1. The diagnosis is tinea incognito. In this case, the clinical appearance of the lesion is altered by the inappropriate treatments with topical corticosteroids.
2. Mycologic investigations, including direct microscopic examination and culturing, are essential. Surface scrapings should be obtained from the border of the lesion where more fungal elements and inflammatory reactions are present. If topical corticosteroids have been applied recently, there may be few surface scales to scrape off and a high risk of false negative results.
3. Topical antifungal agents, such as ciclopirox and terbinafine, are appropriate.

Provided by: Dr. Francesca Cheung

Case 6

Expanding Rash

A 37-year-old male presents with a scaly, itchy, expanding rash on his neck.

Questions

1. What is your diagnosis?
2. Which organism is most likely responsible?
3. How would you manage this patient?

Answers

1. Tinea barbae
2. The dermatophyte *Trichophyton tonsurans* is likely responsible.
3. Topical antifungals, such as ketoconazole, ciclopirox olamine, or terbinafine, are effective for localized disease when used for two to six weeks. Oral antifungals may be required for more extensive involvement or in resistant cases.

Provided by: Dr. Benjamin Barankin

Case 7

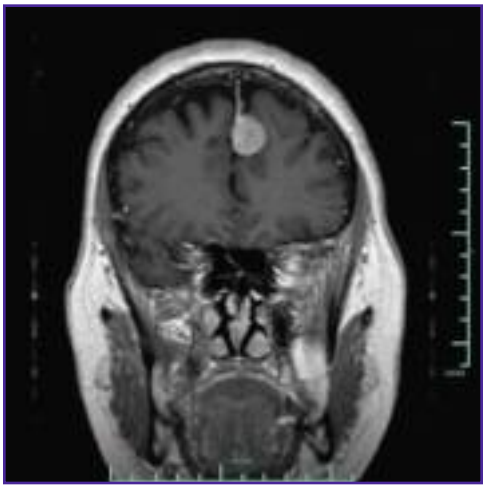

Loss of Consciousness

A 58-year-old, right handed female presents to the ED with two episodes of brief loss of consciousness, accompanied with shaking of both sides of the body that lasted for about two minutes. There was no tongue biting or incontinence of bowel or bladder. An MRI of the brain was performed.

Questions

1. What is seen on this MRI scan?
2. What is your diagnosis?
3. How will you manage this case?

Answers

1. This is a coronal view of T1 weighed MRI brain with contrast showing extra axial space occupying lesions with post contrast enhancement attached to the midline falx cerebri anteriorly with central calcification, which is consistent with a calcified meningioma.
2. This patient had a generalized seizure, likely due to meningioma.
3. A neurosurgical consultation for excision of the meningioma should be obtained. The patient should be started on antiepileptic medication, such as phenytoin 300 mg daily. An EEG may help in localizing the seizure focus further.

Provided by: Dr. Abdul Qayyum Rana, Humaira Rizvi, Dr. A.N. Rana, and Dr. I.U. Haq

Case 8

Circumferential Lip Redness

A six-year-old boy presents with a two-and-a-half week history of a pruritic and progressively enlarging erythematous region surrounding his lips. There is no history of contact with new soaps or lotions. A fine scaling is also visible along the border of the rash.

Questions

1. What is the diagnosis?
2. How is it diagnosed?
3. What is the treatment?

Answers

1. Lip-licking dermatitis
2. This is primarily a clinical diagnosis. There is usually a consistent history of lip-licking, and it often occurs in dry and cold weather. Chronic lip-licking can lead to lichenification of the affected area.
3. The patient should be encouraged to stop licking his lips to break the irritation-licking cycle. Emollients, such as petroleum jelly, can be applied b.i.d. to t.i.d. until a good effect is achieved.

Provided by: Dr. Emmanuel Ogali and Dr. Karen Choi

Case 9

Tattoo Complications

A 25-year-old male visits the clinic with recent complaints of chronic tiredness. A few months ago, he visited a tattoo shop where he had the tattoo on his right forearm done. He asks about complications from the tattoo and the possibility of permanent removal.

Questions

1. What kind of risks are associated with tattoos?
2. Can tattoos be removed easily?
3. What is the management?

Answers

1. Risks include local skin infections, contraction of a variety of blood-borne diseases, such as hepatitis B, hepatitis C, tuberculosis, tetanus or HIV, minor skin reactions (contact dermatitis), and serious allergic reactions to the tattooing method or dye. Scarring, including raised scar tissue (keloids), is also a risk. Traditional metallic salts are prevalent in tattoo inks. A three by five inch tattoo may contain from 1 to 23 micrograms of lead; lead exposure has been linked to birth defects, cancer, and other reproductive harm. Organic pigments (non-heavy metal pigments) may also pose health concerns, and under 20% of colourants contain a carcinogenic. A few cases of burns on tattoos caused by MRI scans have been documented. Problems tend to occur with designs containing large areas of black ink, since black commonly contains iron oxide; the MRI scanner causes the iron to heat up, either by inducing an electrical current or hysteresis. Burning can occur on smaller tattoos, such as "permanent makeup," but this is rare. Non-ferrous pigments have also been known to cause burns during an MRI. It should be stressed that tattoo burns are rare, so merely having a tattoo should not prohibit an MRI scan if necessary.
2. Tattoos should be considered permanent. Tattoo removal is difficult and may cause scarring. Restoration of normal skin colour and texture is difficult.
3. A complete medical exam, chest x-ray, Monteux test, and blood work (CBC, chemistry, including LFT, KFT, and TFT to rule-out Hepatitis B and C and HIV, and lead serum level) should be conducted.

Provided by: Dr. Jerzy K. Pawlak and Dr. Ted Kroczak

Case 10

Unsightly Lesion

A 15-year-old girl complains of an unsightly lesion on her abdomen that has been present in a flatter form since infancy.

Questions

1. What is your diagnosis?
2. Where are these lesions most commonly found?
3. How would you manage this lesion?

Answers

1. Linear epidermal nevus
2. It is common on the trunk and limbs and uncommon on the face and scalp.
3. Reassure the patient as to the benign nature of the lesion. Surgical excision or laser ablation are options to improve cosmesis.

Provided by: Dr. Benjamin Barankin

Case 11

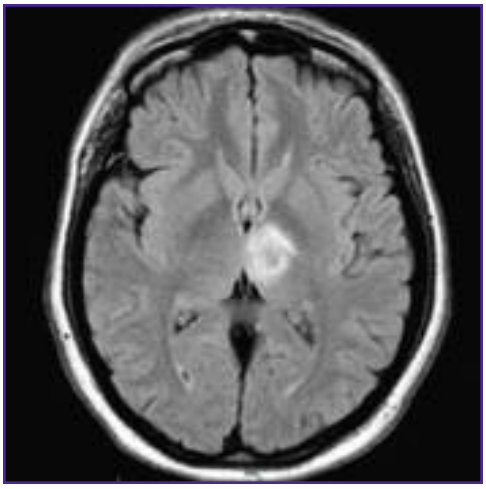

Difficulty Finding Words

A 41-year old, right handed female presents with difficulty finding words during conversation. Her speech is grammatically erroneous with paraphasic errors. The rest of her neurological exam was normal. An MRI of the brain was performed.

Questions

1. What does this MRI scan show?
2. What is your diagnosis?
3. How will you manage this case?

Answers

1. This is an MRI of the brain axial view showing a lesion in the left thalamus of mixed signal intensity. The size of the lesion is 1.2 cm by 1.4 cm by 1.6 cm.
2. Left thalamic ischemic infarct, causing aphasia
3. This patient should be started on antiplatelet therapy, such as aspirin, and a cholesterol-lowering agent. Further stroke workup, including a lipid profile, should also be done. Holter monitoring and 2D echo-cardiogram should be done to rule out cardiac abnormalities.

Provided by: Dr. Abdul Qayyum Rana, Dr. A.N.Rana, and Humaira Rizvi