



# Scalp Hair Loss

Benjamin Barankin, MD, FRCPC

A 47-year-old female with a family history of hair loss presents with a slowly widening hair part and hair loss. There is no hair shedding. She has not had any major stress or surgery, nor has she had weight fluctuations. Her scalp is asymptomatic.

## 1. What is the most likely diagnosis?

- Diffuse alopecia areata
- Androgenetic alopecia
- Tinea capitis
- Lichen planopilaris
- Telogen effluvium

## 2. Which race of people is least commonly affected?

- Caucasian
- Asian
- African
- Native American
- Middle Eastern

## 3. How could you manage this condition?


- Minoxidil
- Oral contraceptive pill
- Spironolactone
- Hair transplant
- All of the above

Androgenetic alopecia (AGA) is a very common genetic condition affecting the scalp hair of approximately 50% of men and women over 40. The incidence of AGA in women dramatically increases after menopause. In addition to the cosmetic effects, hair loss allows more ultraviolet radiation to hit the scalp and thus increases the risk of skin damage and skin cancers. Caucasians are most affected, while Native Americans and Inuits are least affected.

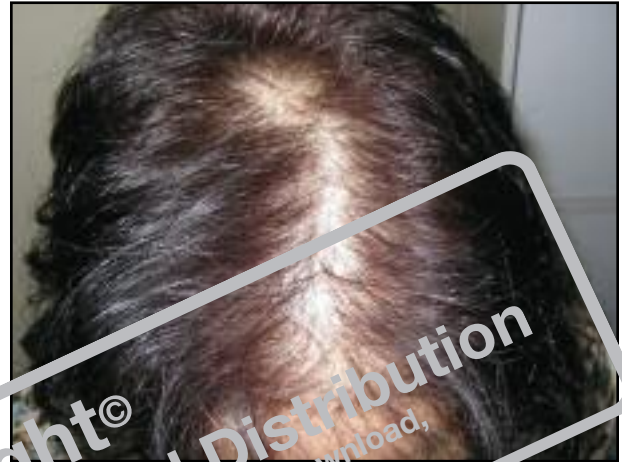

Figure 1: Hair loss on patient's scalp

Women typically present with a diffuse thinning on the crown, and unlike men, bitemporal recession is much less noticeable, with women maintaining the frontal hairline in most cases.

Management involves the use of topical minoxidil in a 2% over the counter preparation, or a 5% prescription solution which has been shown to be more effective. The solution is applied twice per day, and generally women respond better than men to the treatment. Oral finasteride at 1 mg q.d. is a useful treatment in men, but uncommonly used in post-menopausal women. Oral contraceptives and spironolactone can be useful treatments in many women. Recently, low-level laser therapy has entered the market; it appears safe, but is of questionable efficacy. Hair transplant surgery has come a long way over the past 40 years, and now can provide a very natural appearance in experienced hands. Hair pieces and topical hair building fibers (e.g., Toppik) are also options to discuss with patients. 

Answers: 1-b; 2-d; 3-e

Dr. Barankin is a Dermatologist in Toronto, Ontario.