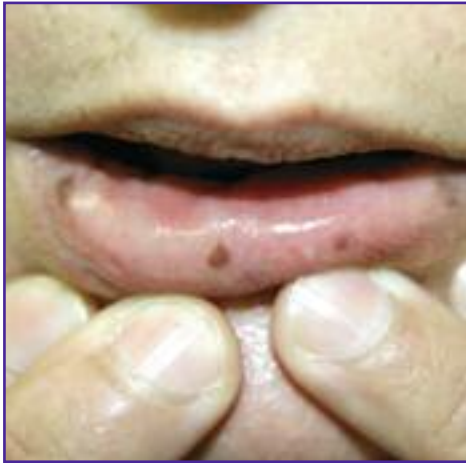



Photo Diagnosis

Illustrated quizzes on problems seen in everyday practice

Case 1



A Pigmented Lesion

A 40-year-old female presented with a pigmented lesion on her lower lip. One lesion has been present for more than three years. The other lesions started to develop within the last year.

Questions

1. What is the diagnosis?
2. What is the significance?
3. What is the management?

Answers

1. Labial melanotic macules.
2. These lesions are directly related to sun exposure. So far all have uniform borders and pigmentation.
3. Observation, avoid sun exposure, using sun-protective lotion, reassess patient in a few months, advice about patient self examination (*i.e.*, looking for any changing of colour when lesion becomes darker or black or when it develops irregular pigmentation or borders).

Provided by: Dr. Jerzy Pawlak

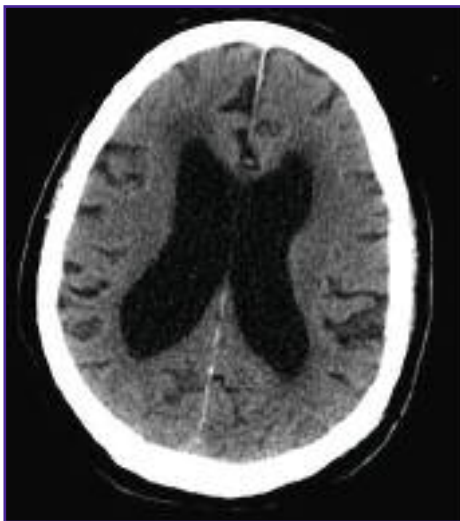
Share your photos and diagnoses with us!

Do you have a photo diagnosis? Send us your photo and a brief text explaining the presentation of the illness, your diagnosis and treatment and receive \$25 per item if it is published.

The Canadian Journal of Diagnosis
955, boul. St. Jean, Suite 306
Pointe-Claire, Quebec H9R 5K3

Email: diagnosis@sta.ca
Fax: (888) 695-8554

Case 2



Cognitive Dysfunction

A 78-year-old female presented with a one-year history gradual onset of memory and cognitive dysfunction, urinary incontinence and balance and gait problems. An MRI brain was performed.

Questions

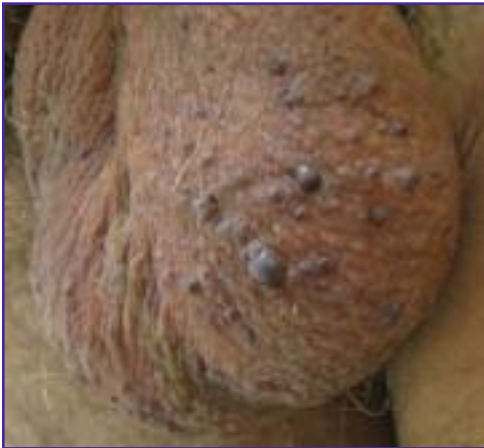1. What does this MRI show?
2. What is the diagnosis?
3. How will you treat this case?

Answers

1. MRI scan shows dilatation of both lateral ventricles.
2. Normal pressure hydrocephalus.
3. Neurosurgical consultation for possible ventriculoperitoneal shunt.

Provided by: Dr. Abdul Qayyum Rana; Dr. Faisal R. Khan; and Dr. Waheed Khan

Case 3



Purple Papules on the Scrotum

A 36-year-old male has a slowly progressing development of purple papules on his scrotum. They occasionally bleed.

Questions

1. What is your diagnosis?
2. What is thought to be the pathogenesis of this condition?
3. How would you manage this condition?

Answers

1. Angiokeratomas of the scrotum (or of Fordyce)
2. While many cases are idiopathic, some cases appear to be due to increased venous pressure.
3. Reassurance as to the benign nature is sufficient for most patients. Otherwise, excision, electrosurgery, or laser are therapeutic options.

Provided by: Dr. Benjamin Barankin

AVAILABLE
SPRING
2010



Easy-to-read
instructions

Easy-grip body

Built-in needle
protection

Labelled orange needle cover
contrasts with blue safety release
for easy orientation

Important Safety Information

EpiPen® and EpiPen® Jr Auto-injectors are indicated for the emergency treatment of anaphylactic reactions in patients who are determined to be at increased risk for anaphylaxis, including individuals with a history of anaphylactic reactions. They are intended for immediate self-administration for the emergency treatment of severe allergic reactions (Type I), including anaphylaxis associated with foods, stinging and biting insects, medications, latex, other allergens, and for idiopathic and exercise-induced anaphylaxis. Selection of the appropriate dosage strength is determined according to patient body weight.

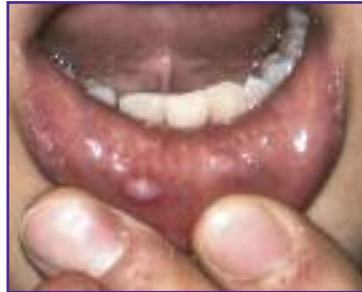There are no absolute contraindications to the use of epinephrine in a life-threatening allergic situation. Epinephrine use should be avoided in patients with cardiogenic, traumatic, or hemorrhagic shock; cardiac dilation; and/or cerebral arteriosclerosis. Epinephrine use should be avoided in patients with organic brain damage and in patients with narrow-angle glaucoma. Administer with caution to elderly or hyperthyroid individuals, pregnant women, and individuals with cardiovascular disease or diabetes.

Adverse reactions of epinephrine include transient, moderate anxiety; feelings of over stimulation; apprehensiveness; restlessness; tremor; weakness; shakiness; dizziness; sweating; tachycardia; palpitations; pallor; nausea and vomiting; headache; and/or respiratory difficulties.

EpiPen® and EpiPen® Jr Auto-injectors are designed as emergency supportive therapy only. They are not a replacement or substitute for subsequent medical or hospital care, nor are they intended to supplant insect venom hypersensitization.

Photo Diagnosis

Case 4



Cystic Mass

A 10-year-old boy presents with a cystic mass on the inner aspect of the lower lip. The mass is asymptomatic. There is no history of trauma.

Questions

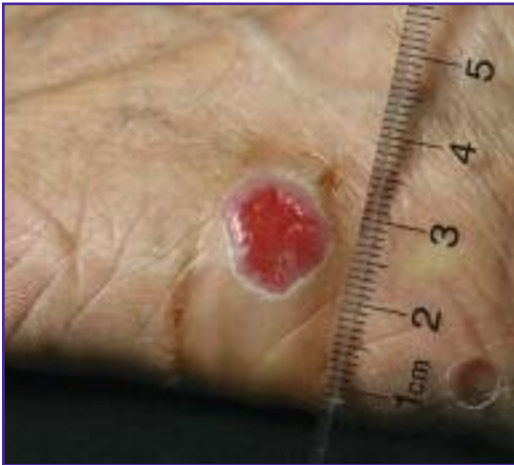1. What is the diagnosis?
2. What is the significance?
3. What is the treatment?

Answers

1. Mucocele.
2. A mucocele is caused by a blockage or traumatic severance of a duct of a minor salivary gland. This leads to extravasation of sialomucin and submucosal retention of the mucus secretion. The overlying mucosa is normal in colour. Typically, a mucocele presents as a painless, fluctuant, tense, cystic mass on the mucosal surface of the lower lip. Occasionally, it may occur on the upper lip, buccal mucosa, gingiva, palate, floor of the mouth, or tongue. The lesion is usually < 1 cm in diameter. The diagnosis is mainly clinical. A mucocele may persist for weeks or months before it ruptures spontaneously. Recurrence is common and may lead to fibrosis.
3. Treatment consists of surgical excision, with extirpation of the involved accessory salivary gland. Other treatment options include drainage followed by coagulation of the sac, CO₂ laser ablation and cryosurgery.

Provided by: Dr. Alexander K. C. Leung; and Dr. Justine H. S. Fong

Case 5



Bleeding Lesion

A 43-year-old avid squash player complains of a bleeding lesion on his foot of six months duration. It has started to affect his game. Examination reveals a 1.5 cm red scaling well circumscribed nodule on the volar aspect of the left foot.

Questions

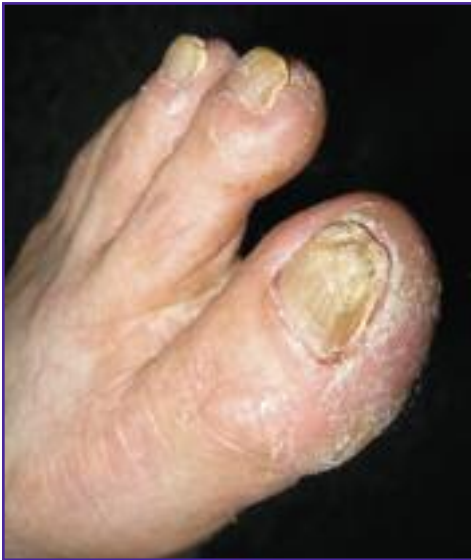1. What is your diagnosis?
2. What is the differential diagnosis?
3. What is the treatment of choice?

Answers

1. Poroma. It is an uncommon, benign adnexal tumour of the skin. Typical lesions develop on the hands and feet in adulthood. There is no racial nor gender predilection. It may be mistaken for a more sinister lesion such as acral melanoma or squamous cell carcinoma. The astute clinician may recognize the lesion by its distinctive collarette of scale surrounding the base of the lesion.
2. Acral melanoma, squamous cell carcinoma, plantar wart and Kaposi sarcoma.
3. Excision is the treatment of choice for diagnosis and symptomatic relief. Pathology reveals a proliferation of epithelial cells that show ductal differentiation of apocrine or eccrine origin.

Provided by: Dr. Simon Lee

Case 6



Discoloured, Brittle Nails

A 54-year-old male presents with thick, discoloured, brittle nails on his feet. His fingernails are not affected.

Questions

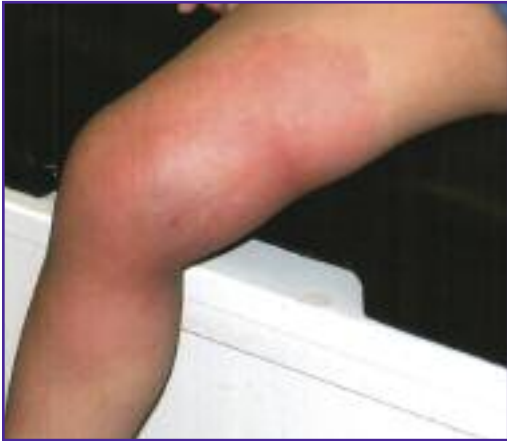1. What is your diagnosis?
2. What are the main subtypes of this condition?
3. How would you manage this patient?

Answers

1. Onychomycosis.
2. Distal lateral subungual onychomycosis (most common), white superficial onychomycosis, proximal subungual onychomycosis (least common) and candidal onychomycosis. Combinations of the above can occur.
3. Topical antifungal creams and lacquers have modest benefit. If instituted early and with only a few nails involved, this is a good starting point, especially if someone is on multiple medications or has liver pathology. Otherwise, oral antifungals (especially terbinafine and itraconazole) are the agents of choice. Surgical nail avulsion is also an option.

Provided by: Dr. Benjamin Barankin

Case 7




Swelling of the Thigh

A nine-year-old boy presents with marked swelling of his right lower thigh and upper leg after playing in a park in the evening. The swelling is markedly pruritic. He had three similar episodes before after playing in the park.

Questions

1. What is the most likely diagnosis?
2. What is the significance?
3. What is the treatment?

Answers

1. Mosquito bite.
2. In an unsensitized individual, a mosquito bite usually results in a slight stinging sensation and a small erythematous, pruritic papule. On the other hand, in a sensitized individual, a mosquito bite may result in an intensely pruritic urticarial wheal which may last several hours to several days. Skeeter syndrome, defined as mosquito-induced large local inflammatory reaction sometimes accompanied by low grade fever, may also result. In the majority of cases, mosquito bites are mostly a nuisance. On the other hand, mosquitoes are vectors of many important diseases such as West Nile virus infection, malaria, dengue fever and yellow fever.
3. Local applications of pramoxine or calamine lotion help soothe the skin. Additional soothing might be obtained by adding menthol and phenol to the topical vehicle. Prophylactic use of an oral antihistamine is effective treatment for both immediate and delayed mosquito bite symptoms and is especially effective in subjects with large wheals. 

Provided by: Dr. Alexander K. C. Leung; and Dr. Justine H. S. Fong