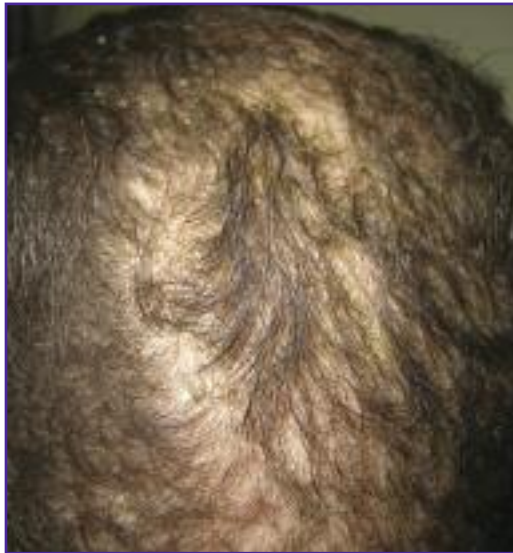



*Illustrated quizzes on problems
seen in everyday practice*

CASE 1: THANE'S THINNING HAIR



Thane, 23, presents with a slowly thinning scalp. He does not note any shedding of clumps of hair in his sink.

Questions

1. What is the diagnosis?
2. Is this a common problem?
3. How would you manage this patient?

Answers

1. Androgenic alopecia. This is a genetically determined and patterned progressive disorder where hair follicles are miniaturized from terminal into vellus hairs.
2. Yes, it affects up to 50% of men and 15% of premenopausal women.
3. OTC minoxidil 2% is available and can be applied twice per day, although prescription strength 5% minoxidil is more effective. Oral finasteride, 1 mg, is also effective and can be used alone or along with minoxidil (the vertex scalp is more responsive to medication than is frontotemporal recession).

Provided by: Dr. Benjamin Barankin

Share your photos and diagnoses with us!

Do you have a photo diagnosis? Send us your photo and a brief text explaining the presentation of the illness, your diagnosis and treatment and receive \$25 per item if it is published.

The Canadian Journal of Diagnosis

955, boul. St. Jean, Suite 306

Pointe-Claire, Quebec H9R 5K3

Email: diagnosis@sta.ca

Fax: (888) 695-8554

CASE 2: PATRICK'S PAIN



Patrick, 15, presents with neck and shoulder pain after receiving a hard hit in a hockey game. An examination shows that he is neurologically intact but has significant tenderness over the spinous process of T1.

Questions

1. What is the diagnosis?
2. What is the significance?
3. What is the treatment?

Answers

1. Patrick is diagnosed with Clay shoveler's fracture.
2. A Clay shoveler's fracture represents an avulsion-type fracture of the spinous processes of the lower cervical or upper dorsal region.

The classical "Clay Shoveler's Fracture" occurs most commonly at the C7 level, but can range from C6 to T3.

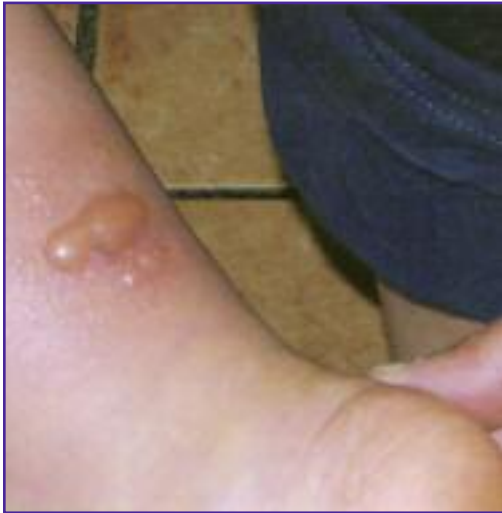It was so named after the association of being frequently sustained by men shoveling clay and the injury results from forceful contraction of trapezius and rhomboid muscles. The fracture can also result from a sudden severe flexion force transmitted to posterior spinous ligaments.

3. Since the injury involves only the spinous process it is deemed stable. The management involves mostly an orthotic device like a soft collar for comfort. Ice, rest and simple analgesics can be used with or without physiotherapy until the symptoms resolve.

Patrick started skating 10 days after the injury and participated in non-contact hockey until he was able to resume full contact sports at four weeks after the injury.

Provided by: Dr. Werner Oberholzer

CASE 3: LESTER'S LESIONS



These characteristic lesions are erythematous urticarial wheal or papules, often with a central punctum.

Lester, a six-year-old boy, is noted to have bullous lesions on his posterior right leg after playing in a park. The lesions are intensely pruritic with surrounding erythema.

Questions

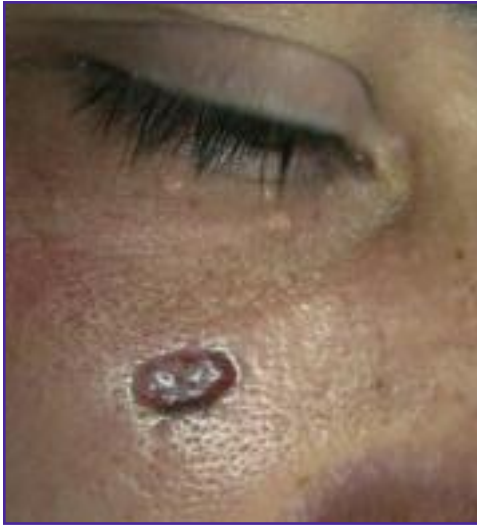1. What is the diagnosis?
2. What is the significance?
3. What is the treatment?

Answers

1. Insect bite.
2. The characteristic lesions of insect bites are erythematous urticarial wheal or papules, often with a central punctum. Bullae can occasionally develop in susceptible individuals, particularly young children, who are hypersensitive to insect venoms or saliva.
3. Symptomatic treatment includes alleviating itching by the use of a topical antipruritic agent, such as camphor and menthol lotion or gel formulation and/or a systemic antihistamine, such as hydroxyzine hydrochloride.

Provided by: Dr. Alexander K. C. Leung; and Dr. C. Pion Kao

CASE 4: FINN'S FACIAL SORE



This condition should always be ruled out in the presence of a non-healing wound or sore on the face.

Finn, 47, is a construction worker who presents with a non-healing sore on his face.

Questions

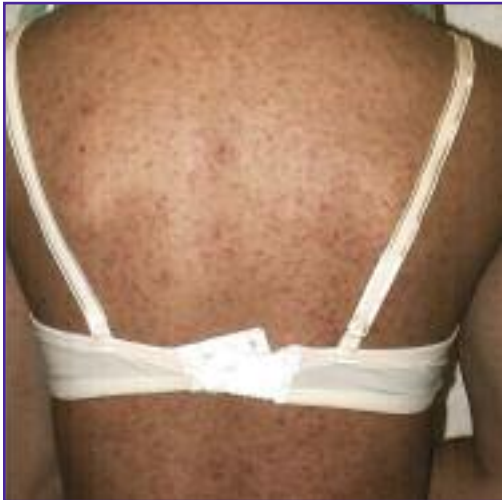1. What is the diagnosis?
2. What are the subtypes of this lesion?
3. How would you treat this lesion?

Answers

1. Basal cell carcinoma (BCC). This should always be ruled out in the presence of a non-healing wound or sore on the face.
2. The common, less aggressive subtypes of BCC are:
 - nodular,
 - superficial,
 - pigmented and
 - cystic.The more aggressive subtypes of BCC are:
 - micronodular,
 - morpheaform and
 - infiltrating.
3. Mohs micrographic surgery would be the ideal option on the face to minimize recurrence and optimize cosmesis. Simple surgical excision or electrodesiccation and curettage are options as well.

Provided by: Dr. Benjamin Barankin

CASE 5: RAMONA'S RASH



Local skin care with antibacterial soaps and the removal of predisposing conditions are important general measures in treating this infection.

Ramona, 13, presents with a 10-day history of a rash on her back and arms. The rash is not itchy. There is no associated fever.

Questions

1. What is the diagnosis?
2. What are the causative organisms?
3. What are the treatment options?

Answers

1. Folliculitis.
2. Folliculitis is a superficial infection of the hair follicles most often caused by *Staphylococcus aureus*. Other organisms such as *Pseudomonas aeruginosa* and *Malassezia furfur* (*Pityrosporum ovale*) might also be responsible.
3. Local skin care with antibacterial soaps and the removal of predisposing conditions, such as poor personal hygiene, are important general measures.

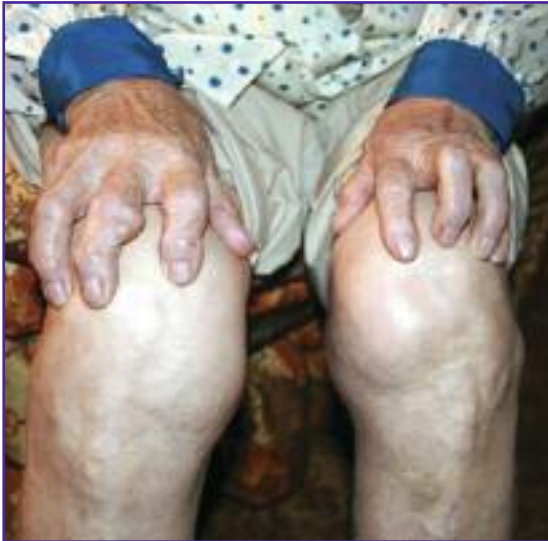Staphylococcal folliculitis usually responds to topical antibiotic therapy. More severe cases may require use of penicillinase-resistant systemic antibiotics, such as dicloxacillin or cephalexin.

Pseudomonas folliculitis usually resolves spontaneously without treatment.

Pityrosporum folliculitis usually responds well to an oral antifungal agent.

Provided by: Dr. Alexander K. C. Leung; and
Dr. Alexander G. Leong

CASE 6: DORIS' DEFORMITY



Doris, 82, presents with recurrent pain, stiffness and deformity of both hands and knees.

Questions

1. What is the diagnosis?
2. What is the treatment?

Answers

1. Degenerative osteoarthritis.
2. The approach of most physicians to the management of osteoarthritis is aimed at reducing joint pain through pharmacological measures. Individualized exercise programs should also be incorporated.

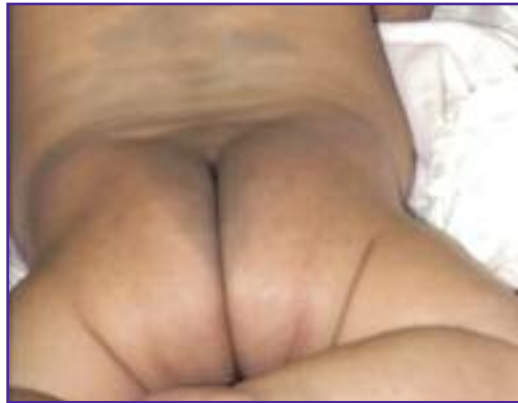In the patient with significant weakness or reduction in joint motion, the initial aim should be to:

- reduce the impairment,
- improve function and
- prepare for increased activity.

Provided by: Dr. Jerzy Pawlak

In the patient with significant weakness or reduction in joint motion, the initial aim should be to reduce the impairment, improve function and prepare for increased activity.

CASE 7: SONG'S GRAY SPOTS



Song, a three-month-old Chinese infant, is noted to have multiple grayish spots over his back, buttocks and ankles.

Questions

1. What is the diagnosis?
2. What is the significance?
3. What is the treatment?

Answers

1. Mongolian spots.
2. Mongolian spots are congenital hyperpigmented macules or patches of varying size and shape. Mongolian spots are usually grayish and vary from gray to gray-blue to gray-black; the younger the child, the darker the colour.

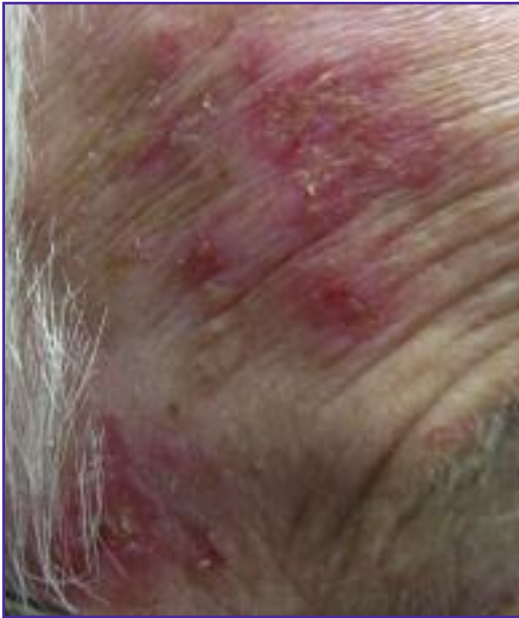Mongolian spots are most common in the sacrococcygeal area, followed by the gluteal and lumbar areas. When Mongolian spots are confused with

contusions, there might be medico-legal implications. Misdiagnosis is more common if the child is comatose and the Mongolian spot is found in an unusual site, such as the scalp or face, or has an abnormal shape. Horizontal and linear Mongolian spots have been reported which simulate contusions inflicted with a stick. Mongolian spots should be documented if they are:

- extensive,
 - occur in unusual sites, or
 - have unusual shapes.
3. Mongolian spots are benign and asymptomatic; therefore, treatment is not necessary.

Provided by: Dr. Alexander K. C. Leung, and
Dr. Alex H. C. Wong

CASE 8: SERGIO'S SCALP




Sergio, 70, was prescribed imiquimod cream for actinic keratoses on his face. He is now complaining of soreness of the scalp.

Questions

1. What is the diagnosis?
2. How would you advise the patient?

Answers

1. This is a typical reaction when using imiquimod which signifies that the immune system has been activated to attack the rapidly-dividing cells of actinic keratoses.
2. If Sergio finds it too uncomfortable, he should stop applying imiquimod and be evaluated a month later. A mild topical steroid can be beneficial and, occasionally, a topical antibiotic is required if the sore becomes secondarily infected. 

Provided by: Dr. Benjamin Barankin

This reaction signifies that the immune system has been activated to attack the rapidly-dividing cells of actinic keratoses.