



“What is this on the tip of my nose?”

Benjamin Barankin, MD, FRCPC

A 36-year-old male presents with an erythematous dome-shaped papule on the tip of his nose that he has had for many months. It is asymptomatic and is not growing. He is concerned about a skin cancer. He is otherwise healthy. He admits to having worked as a life-guard in his teenage years and had several sunburns at that time.

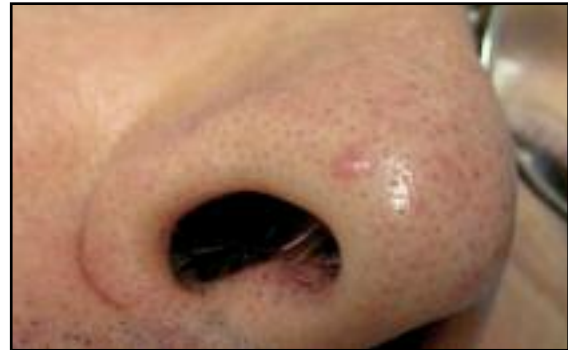

Figure 1. Papule on tip of nose.

1. What is the most likely diagnosis?

- Basal cell carcinoma
- Acne papule
- Neurofibroma
- Scar
- Angiofibroma

2. If multiple lesions are found on the face, what other conditions should be considered?

- Tuberous sclerosis
- Multiple endocrine neoplasia
- Neurofibromatosis
- Sarcoidosis
- a & b

3. What is a reasonable management option?


- Reassurance
- Shave excision
- Electrosurgery
- Laser
- All of the above

An angiofibroma is a common, small, benign, papule most commonly seen on or near the nose. Most lesions present in adulthood and are generally asymptomatic. The appearance is

flesh-coloured or pink and often shiny. Usually, only one lesion is noted, though several are possible. The vast majority of cases are non-hereditary solitary lesions, although multiple hereditary lesions are noted in tuberous sclerosis and multiple endocrine neoplasia Type 1. The differential diagnosis would include:

- basal cell carcinoma,
- acne papule,
- angioma,
- neurofibroma and
- compound nevus.

The histopathology characteristically reveals proliferation of fibroblasts within a fibrotic stroma and the presence of dilated blood vessels.

Angiofibromas are benign, but may be treated for cosmetic purposes. Treatment options include gentle electrosurgery, laser, shave excision, or curettage. 

“Case in Point” is a series of interesting cases and diagnoses so general practitioners can sharpen their skills. Submissions and feedback can be sent to diagnosis@sta.ca.

Dr. Barankin is a Dermatologist practicing in Toronto, Ontario.

Answers: 1-e; 2-e; 3-e