



“Mommy, what’s wrong with my head?”

Jerzy K. Pawlak, MD, MSc, PhD; and T. J. Krocak, BSc

Jimmy, seven-years-old, was brought to the clinic because of recurrent headaches after a minor head injury.

Medical history

Jimmy’s medical history reveals that up until the injury, he was healthy and has an unremarkable family history. He has two older brothers, both of whom are healthy. Academically, Jimmy is below average.

Physical examination

A physical examination notes that:

- Jimmy’s current head circumference is 56 cm. His father’s head circumference is 58 cm
- At six-months-of-age, Jimmy’s head circumference was 43 cm
- His physical and neurological examinations are within normal limits

Clinical investigations

The following clinical investigations show:

- A normal complete blood count, liver function tests and urine analysis
- A normal chest x-ray
- A normal EKG
- CT scans of Jimmy’s brain reveal axial CT cuts (Figures 1, 1a, 1b, 1c, 1d, 1e)

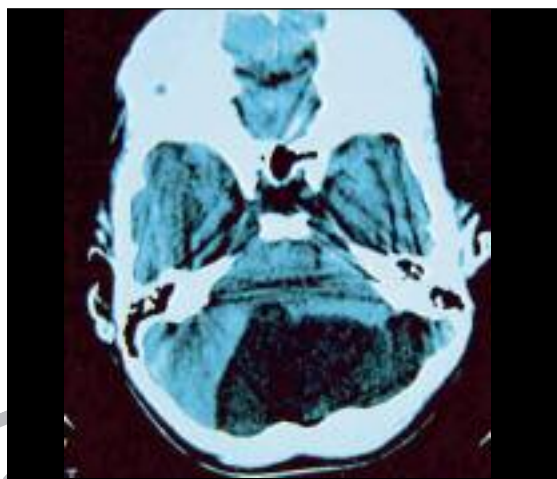


Figure 1. CT scan of brain.

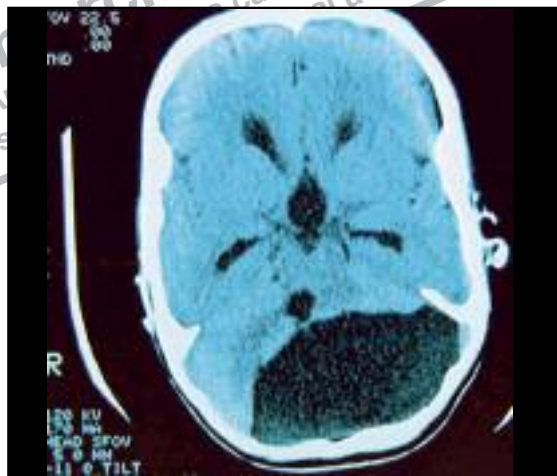

Figure 1a. CT scan of brain.

What’s your diagnosis?

- a) Brain tumour
- b) Dandy-Walker malformation
- c) Arachnoid cyst
- d) Dandy-Walker variant

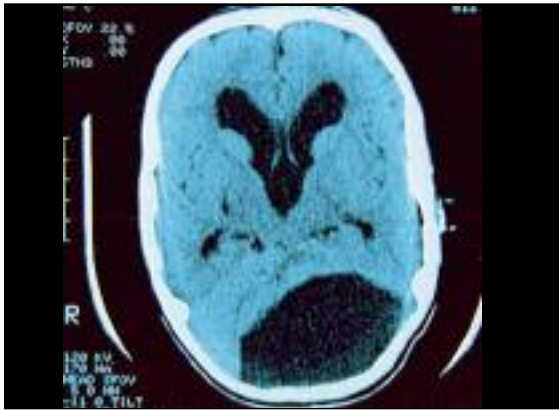

Figure 1b. CT scan of brain.

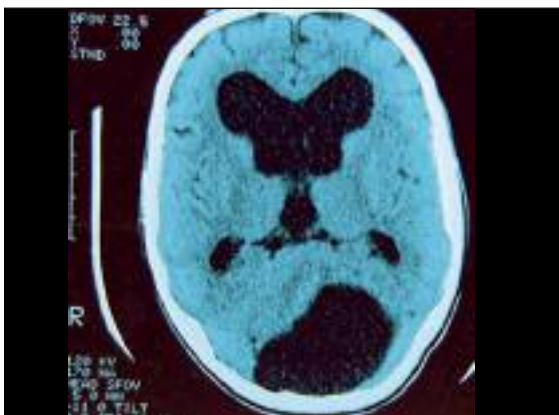


Figure 1c. CT scan of brain.

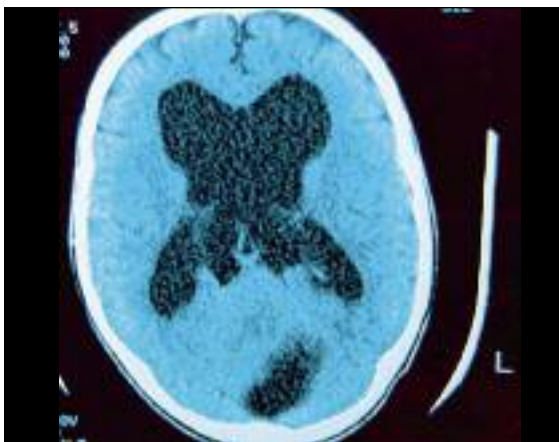

Figure 1d. CT scan of brain.

Answer: B or D

What is Dandy-Walker malformation?

The true cause of Dandy-Walker malformation (DWM) is unknown. However, the components of the malformation seem to be related to a disruption in the development of the middle portion of the lower part of the brain in the embryonic stage. This affects the growth and development of the cerebellum, especially the vermis and the brainstem such that the foramina of Magendie and Luschka are partially or completely closed.

Mental and intellectual functions are depressed in half of patients with DWM. The other 50% may have normal cognitive functions.

Mental and intellectual functions are depressed in half of patients. The other 50% may have normal cognitive functions. The degree of symptoms depends on the gravity of the congenital disease. If the child has severe malformations from birth, the signs may appear at early ages, but sometimes symptoms of the disease may be unnoticed until adulthood. Sometimes the only symptom can be the abnormal enlargement of the head. Some children may appear with signs of increased

intracranial pressure which include:

- vomiting,
- convulsions,
- agitation, or
- signs of impaired cerebellar function such as:
 - equilibrium problems (dizziness)
 - abnormal eye movements (nystagmus).

Presentation

Classically, posterior fossa cystic malformations has been divided into:

- DWM,
- Dandy-Walker variant/triad (consists of vermian hypoplasia and cystic dilatation of the fourth ventricle without enlargement of the posterior fossa),¹
- mega cisterna magna and
- posterior fossa arachnoid cyst.

Precisely differentiating the malformations may not be possible using imaging methods.

Treatment

The primary treatment for DWM and associated hydrocephalus is the placement of a ventriculoperitoneal shunt. In some cases, an endoscopic fenestration procedure can be performed. In this procedure, a small, flexible viewing device, called an endoscope, is inserted into the brain and an opening is made between the third and fourth ventricles or in the foramina at the base of the brain. Other

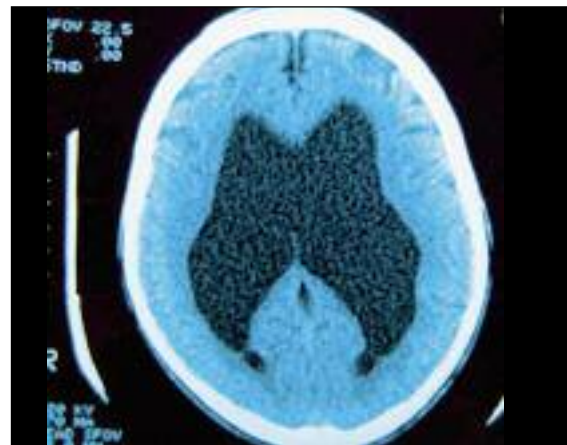


Figure 1e. CT scan of brain.

treatments include those for the symptoms of hydrocephalus and cerebellar agenesis, such as anti-seizure medications and for neuromuscular problems.

Back to Jimmy

Jimmy has been accidentally diagnosed because he developed recurrent headaches after a minor head injury. His axial CT cuts were obtained through the brain, including posterior fossa which showed an approximately 9 cm by 4.9 cm cerebral spinal fluid attenuation cyst in the posterior fossa in the midline and extending to the left of midline. The cyst communicates with the fourth ventricle. There is an elevation of the cerebellar vermis with hypoplasia of the left cerebellar hemisphere. These findings are most consistent with a DWM or a Dandy-Walker variant. **Dx**

Dr. Pawlak is a General Practitioner, Winnipeg, Manitoba

Mr. Krocak is a Second Year Medical Student, University of Manitoba, Winnipeg, Manitoba.

Reference

1. Incesu I, Khosla A: Dandy-Walker Malformation. In: Glasier CM, et al (eds.): *eMedicine.com*. <http://www.emedicine.com/radio/topic206.htm>