



“Is this lesion cancer?”

Benjamin Barankin, MD

A 64-year-old man presents requesting a total cutaneous exam in light of a previous history of sunburns in childhood and years of working on a farm.

He has no specific concerns and is unaware of a lesion on his back (Figure 1).

The patient has Type 2 diabetes, which is diet-managed. He is not taking any medications.

1. What is the most likely diagnosis?

- a) Tinea corporis
- b) Granuloma annulare
- c) Dysplastic nevus
- d) Pigmented basal cell carcinoma
- e) Melanoma

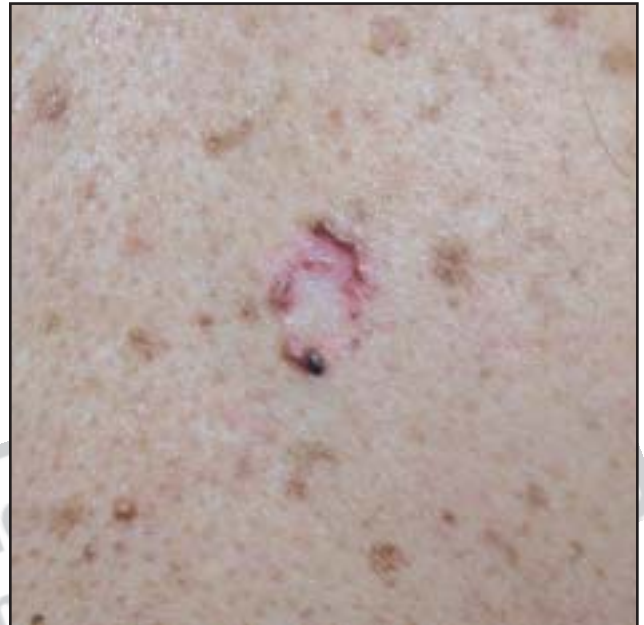


Figure 1. Patient showing lesion on his back.

2. What is the main concern with this lesion?

- a) Its appearance
- b) The possibility of local spread
- c) The possibility of metastases
- d) It suggests the patient is immunosuppressed
- e) It may be contagious

3. How could you treat this lesion?

- a) Imiquimod cream
- b) Aggressive cryotherapy
- c) Electrodesiccation & curettage
- d) Excision
- e) All of the above 

Dr. Barankin is a dermatology resident, University of Alberta, Edmonton, Alberta.

“Case in Point” is a series of interesting cases and diagnoses so general practitioners can sharpen their skills. Submissions and feedback can be sent to diagnosis@sta.ca.

Answers: 1-d; 2-b; 3-e