



“I can’t sleep ‘cause of my tender ear!”

Benjamin Barankin, MD

A 74-year-old healthy man presents with a four-month history of a persistent, painful, crusted papule on the helix of his right ear (Figure 1). He reports the nodule wakes him from sleep when he turns onto his ear. He has tried some over-the-counter salves, but they have not helped.

1. What is the most likely diagnosis?

- a) Squamous cell carcinoma
- b) Hypertrophic actinic keratosis
- c) Eczema
- d) Chondrodermatitis nodularis chronica helicis
- e) Keratoacanthoma

2. What is the main concern with this lesion?

- a) It is painful
- b) It disrupts sleep
- c) It can spread locally
- d) It can metastasize
- e) a & b

3. How might you treat this lesion?


- a) A special pillow with an area cut out for the ear
- b) Potent topical or intralesional steroids
- c) Excision
- d) Cryotherapy
- e) All of the above 

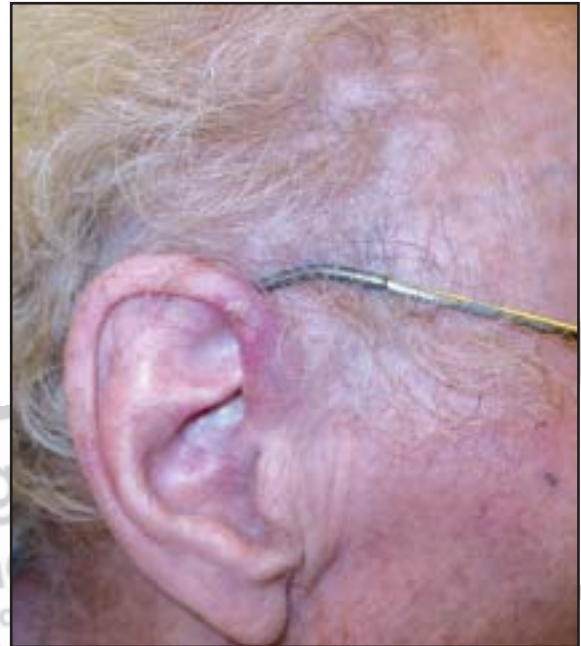

Figure 1. Patient showing persistent, painful, crusted nodule on the helix of his right ear.

Dr. Barankin is a dermatology resident, University of Alberta, Edmonton, Alberta.

“Case in Point” is a series of interesting cases and diagnoses so general practitioners can sharpen their skills. Submissions and feedback can be sent to diagnosis@sta.ca.

Answers: 1-d; 2-e; 3-e