She's Gonna Blow!

Fizzah Aziz Choudry, BSc; Kirk Magee, MD, MSc, FRCPC; and Robert Green, MD, FRCPC

A 77-year-old women presents to the emergency department (ED) complaining of gradual onset, occipital headache. Her blood pressure (BP) is 200/118 mmHg and her electrocardiogram (ECG) is shown in Figure 1.

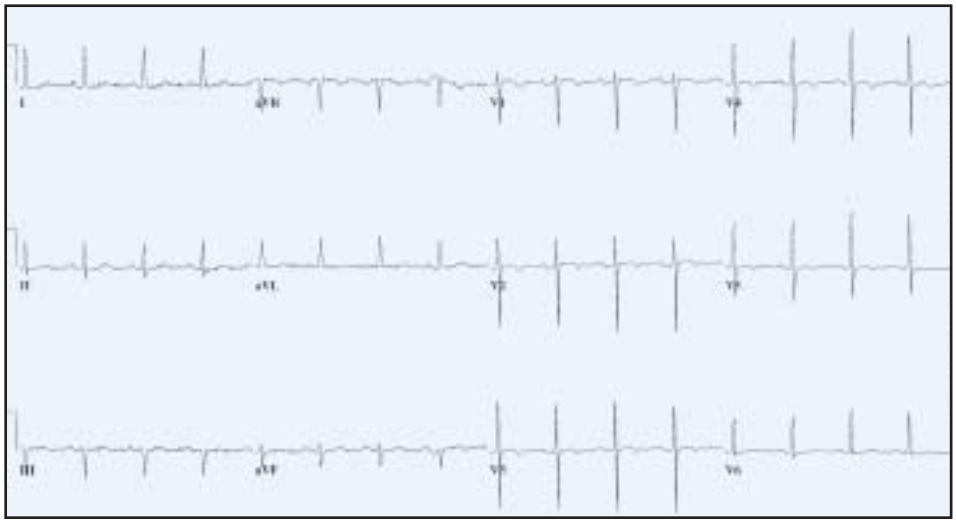

Figure 1. Patient's ECG.

The patient explains she was started on hydrochlorothiazide three weeks ago for high BP. She denies chest pain, dyspnea, visual changes, slurred speech, paralysis, or parethesia.

On exam, the patient appears comfortable and has a heart rate of 104 beats per minute. Her BP in the other arm is 200/102 mmHg. The rest of her exam is normal.

Questions:

1. ***How do you classify hypertension in the ED?***
2. ***What are the key elements in the history?***
3. ***What are the key elements in a focused physical exam?***
4. ***What are the key investigations?***
5. ***What are the principles of treating a patient in hypertensive emergency?***

Answers:

1. *How do you classify hypertension in the ED?*

Hypertension in the outpatient population is defined as BP > 140/90 mmHg and classified thereafter into hypertension stages 1, 2, and 3 according to the degree of BP elevation (Table 1).

However, BP management in the ED depends more on the individual's clinical condition than on absolute values of systolic or diastolic pressure. In the ED, hypertension tends to present in four main ways:

1. *Hypertensive emergency*: Stage 3 hypertension with evidence of target organ damage/ischemia.
2. *Hypertensive urgency*: Stage 3 hypertension with imminent risk, but no evidence of target organ damage/ischemia.
3. *Acute hypertensive episode*: Hypertension without imminent risk or evidence of target organ damage/ischemia.
4. *Transient hypertension*: Hypertension related to anxiety, pain, or patient's primary complaint.

2. *What are the key elements in the history?*

The clinical evaluation of patients presenting to the ED with hypertension is directed towards assessing target

Table 1

Classification of hypertension
(Joint National Committee on Prevention, Detection, Evaluation, and Treatment of High Blood Pressure)

Stage	Systolic BP (mmHg)	Diastolic BP (mmHg)
1	140-159	90-99
2	160-179	100-109
3	≥ 180	≥ 110

BP: Blood pressure

Table 2

Symptoms of target organ damage

System	Symptoms
CNS	Headache, diplopia, blurring of vision, confusion, seizures, hemiparesis
Cardiovascular	Chest pain, dyspnea, tachycardia, palpitations
Renal	Hematuria, anuria

CNS: Central nervous system

organ damage to differentiate hypertensive emergencies from urgencies. Particular attention should be paid to presenting symptoms and their duration, which may indicate target organ damage (Table 2).

Inquiry of prior diagnoses of hypertension, treatment received, and compliance with medications is essential. Also, history of cardiovascular, cerebrovascular, renal disease, diabetes mellitus, hyperlipidemia, or chronic obstructive pulmonary disease suggests an increased risk of target organ damage.

Over-the-counter drugs, illicit drugs, and monoamine oxidase inhibitors can all elevate BP.

3. *What are the key elements in a focused physical exam?*

Airway, breathing, and circulation should initially be assessed in patients with symptoms possibly related to elevated BP. Measuring vital signs is critical to the assessment process. Special care must be taken to use an appropriately sized cuff when measuring BP, as a cuff that is too short or narrow may cause falsely elevated readings. If elevated, BP measurement should be repeated in both arms.

The focus of the physical exam should be the detection of target organ damage and determination of its acuity (Table 3).

4. *What are the key investigations?*

Key investigations focus on the detection of target organ damage related to elevation in BP. An ECG should be performed and compared with previous ECGs for any signs of ischemia. Signs include T-wave inversion of myocardial ischemia, ST abnormalities of left ventricular strain and hypertrophy, ST depression or Q waves, and ST elevation and T-wave inversion of acute coronary syndromes.

A complete blood count may demonstrate microangiopathic hemolytic anemia resulting from vascular damage. Blood urea, creatinine, and electrolyte levels, along with urinalysis may reveal renal impairment. A chest X-ray may show acute congestive cardiac failure or aortic dissection.

The need for additional, specialized diagnostic studies, such as a head computed tomography and echocardiography is dictated by clinical findings.

5. *What are the principles of treating a patient in hypertensive emergency?*

Patients with hypertensive emergencies require immediate reduction of BP with intravenous antihypertensive medications. Reductions in BP should be performed in a

Table 3

Target organ exam findings

System	Exam findings
CNS	Mental status; focal neurologic findings indicating hypertensive encephalopathy, stroke, or subarachnoid hemorrhage
Optic signs	Grade III/IV retinopathy (hemorrhages & hard exudates [vessel leakage]); cotton wool spots (focal ischemia); disc edema (hypoxia); grade I/II retinopathy suggests chronic hypertension
Cardiovascular	Heart sounds (S_3 in ventricular failure, S_4 in left ventricular hypertrophy); pleural effusion/evidence of congestive cardiac failure murmurs; pericardial rub; peripheral pulses

CNS: Central nervous system

graded manner so that reductions do not exceed 20% to 25% within the first 30 to 60 minutes. Decreasing BP more than 25% below baseline mean arterial pressure may lead to hypoperfusion of the brain.

The patient's clinical presentation dictates medication choice. Sodium nitroprusside and labetalol are both considered first-line therapies for most hypertensive emergencies. Labetalol can be used (20 mg intravenously, as needed) or administed as an infusion, whereas sodium nitroprusside can only be administered as an infusion.

The treatment goal in hypertensive urgencies is a gradual reduction of BP over a period of 24 hours using oral antihypertensives. Beta blockers are indicated in patients with acute coronary syndromes; diuretics are indicated in renal disease, congestive cardiac failure, and volume overload; and angiotensin-converting enzyme inhibitors can be used in patients with a history of congestive cardiac failure and diabetes mellitus.

Admission to hospital depends on comorbidity and anticipated response to therapy.

Back to our patient...

Other than complaining of a headache, our patient has no symptoms of end organ damage. However, the ECG demonstrates signs of myocardial ischemia, with T-wave changes throughout the anterior leads (Figure 1).

The patient is diagnosed with a hypertensive emergency. She is treated with labetalol, 20 mg intravenously.

Over a period of 20 minutes, her headache resolves and her heart rate and BP decrease to 75 beats per minute and 160/85 mmHg, respectively. Most importantly, the signs of ischemia on her ECG resolve.

Subsequent lab work, including a complete blood count, electrolytes, renal function, and cardiac enzymes, are all normal.

The patient is admitted to hospital for further monitoring and investigation.

This department covers selected points to avoid pitfalls and improve patient care by family physicians in the ED. Submissions and feedback can be sent to diagnosis@sta.ca.

Ms. Choudry is a medical student, University College, London, U.K.

Dr. Magee is a an ED physician, Queen Elizabeth II Health Sciences Centre, Halifax, Nova Scotia.

Dr. Green is an assistant professor, Dalhousie University, and an emergency physician and intensivist, Queen Elizabeth II Health Sciences Centre, Halifax, Nova Scotia. Dx