Out-of-the-Norm Vermiform

Solange M. Dias, BSc, BScN, RN, MD; and Peter G. Katis, BSc, MD, CCFP(EM)

A 49-year-old woman presented to the emergency department (ED) with a two-day history of constant, non-radiating, epigastric pain of sudden onset with some spontaneous improvement on arrival. There was no associated shortness of breath, chest discomfort, palpitations, diaphoresis, nausea, or emesis prior to or following the onset of pain. Her discomfort was not associated with meals and was not exacerbated by lying supine. She had one bowel movement while in the ED. There was no evidence of melena, hematochezia, or mucous. Her stooling pattern in the preceding days was also unremarkable. There was no anorexia, fever, chills, or weight loss. Her dietary patterns were unchanged and she had no history of travel or infectious contacts.

The past medical history was negative for cardiovascular disease, pulmonary disease, peptic ulcer, hepatobiliary disease, and diabetes. There was no previous history of hospitalization or surgery. She had never experienced similar symptoms in the past and her family history was unremarkable. She was not taking any prescription drugs, over-the-counter products, or herbal medications and she had no allergies. The patient's vital signs were:

- Blood pressure: 110/72 mmHg
- Heart rate: 88 beats/minute
- Respiratory rate: 20 breaths/minute
- Temperature: 36.7 C
- Oxygen saturation: 99% on room air

Results of the physical exam are recorded in Table 1.

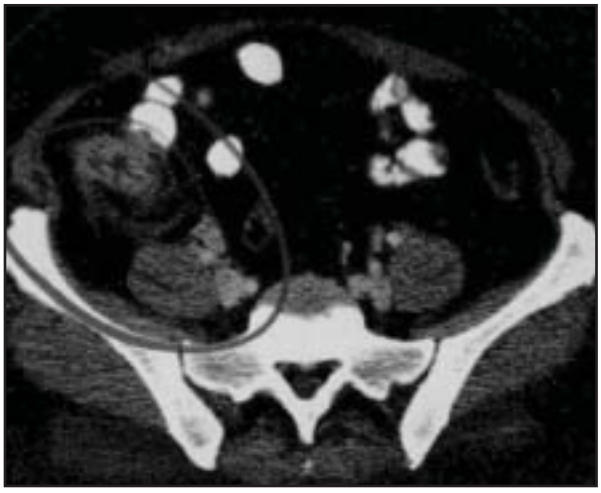

Figure 1. Computed tomography scan of the abdomen and pelvis.

Table 1

Physical exam results

- General appearance: No pallor, cyanosis, jaundice, or signs of dehydration
- Cardiovascular: Normal
- Respiratory: Normal
- Abdominal:
  - Abdomen: Obese
  - Bowel sounds: Normal
  - Abdomen: Soft, no masses, no ascites
  - Mild tenderness elicited at epigastrium but most tender in the right, lower quadrant at McBurney's point
  - Rebound tenderness present
  - Rovsing's sign: Negative
  - Obturator test: Negative
  - Digital rectal exam: Normal
  - No costovertebral angle tenderness
- Pelvic exam: Normal

What investigations were done?

Her lab exam results are listed in Table 2.

Her electrocardiogram showed normal sinus rhythm with no ischemic changes and the chest X-ray was normal. The patient was sent for an abdominal ultrasound, which revealed a gallbladder with a mobile 1.6-cm calculus. In addition, a prominent bowel loop measuring 5.6 cm x 2.5 cm x 2.6 cm was appreciated in the right, lower quadrant, which coincided with her point of maximal tenderness. This finding suggested either an inflamed and thickened appendix, or possibly an inflamed terminal ileum. It was recommended that the ultrasound be followed up with a computed tomography (CT) scan. A subsequent intravenous and oral enhanced CT scan (Figure 1) of the abdomen and pelvis showed an ill-defined lobulated inflammatory mass measuring approximately 3 cm x 4 cm within the right, lower quadrant. An appendix separate from this mass could not be appreciated.

What's your diagnosis?

a) Crohn's disease
b) Ruptured appendix
c) Adenocarcinoma of the appendix
d) Bladder carcinoma

Dr. Dias is a family medicine resident, department of family and community medicine, University of Toronto, Toronto, Ontario.

Dr. Katis is a lecturer, department of family and community medicine, University of Toronto, and the assistant medical director of emergency medicine, University Health Network, Toronto, Ontario.

Table 2

Lab exam results

- White blood cells: 11.8 x 10^9/L
- Hemoglobin: 125 g/L
- Platelets: 232 x 10^9/L
- Liver and amylase tests: Within normal range
- HCG: Negative

HCG: Human chorionic gonadotropin

Answer: Adenocarcinoma of the appendix

The patient was referred to general surgery for an acute appendicitis and to rule out perforation. An appendectomy was performed and the specimen was sent for pathologic analysis. The analysis revealed a well-differentiated, mucin-secreting type adenocarcinoma of the vermiform appendix.

The vermiform appendix is derived embryologically from the large intestine. Given this association, it is important that clinicians understand that neoplasms of the large bowel may also occur in the appendix.

Adenocarcinoma of the vermiform appendix, the condition diagnosed in this patient, is a rare neoplasm which represents < 0.5% of all the gastrointestinal neoplasms. It often arises from adenomata, which are benign lesions with histologic nuclear atypia. Adenocarcinoma of the appendix is more

Share your cases with us!

Our mailing address:
955 boul. St-Jean,
Suite 306
Pointe-Claire, Quebec
H9R 5K3

Our fax number:
1-888-695-8554

Our e-mail address:
diagnosis@sta.ca

common in men and tends to present at approximately 50 years of age.

Two-thirds of patients with appendiceal adenocarcinoma present with signs suggesting acute appendicitis, however the correct diagnosis is made in less than half of these cases, even at the time of surgery.

Appendicitis is precipitated by occlusion of the narrow appendiceal lumen by the neoplasm early in its course. The remaining one-third of patients present with an abdominal mass, which may be confused with Crohn's disease, intussusception, hydronephrosis, or bladder carcinoma. Ultrasonography, CT, or barium enema will aid in differentiating between these conditions. Deficiencies in both longitudinal and circular muscle fibres will predispose the appendix to perforation. In these cases, patients may present with abdominal distention, splenic or hepatic masses, or fistulas.

2/3 of patients with appendiceal adenocarcinoma present with signs suggesting acute appendicitis; the correct diagnosis is made in < 1/2 of these cases.

What is the prognosis?

The prognosis of adenocarcinoma of the appendix is based on its staging and is similar to that of colorectal carcinomas. The degree of tumour invasion is the most important factor in determining treatment. Right hemicolectomy is the treatment of choice for all lesions with invasion beyond the mucosa, irrespective of histologic type or degree of differentiation. In the presence of tumour invasion, the five-year survival rate after hemicolectomy is 60%, compared to 20% for appendectomy alone. Approximately 20% of patients will develop a second primary synchronous or metachronous malignancy, hence followup surveillance is warranted in the remainder of the gastrointestinal tract.

The patient in this case underwent a right hemicolectomy during a subsequent second surgery and is currently being closely followed.

It is important to increase awareness of this rare, but potentially fatal, neoplasm. Dx