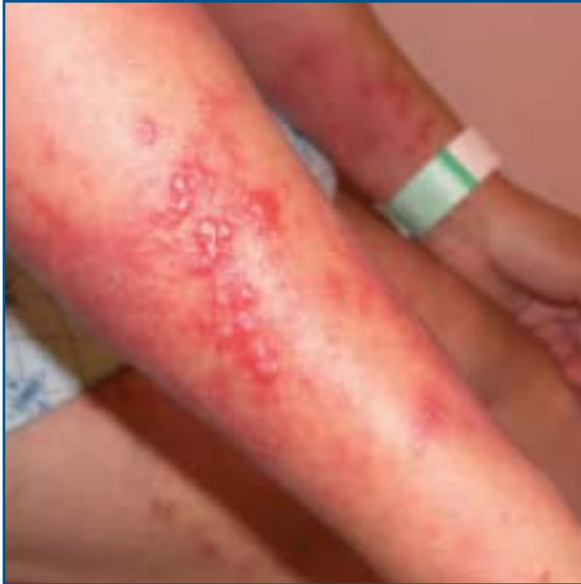



# Photo Diagnosis

*Illustrated quizzes on  
problems seen in everyday practice*



## Case 1

A 50-year-old woman presented with pruritic erythematous plaques, vesicles, and bullae on her arms, legs, and perivulvar region. Some lesions appeared to have a linear configuration. She had been gardening two days earlier.

## Questions

1. What is the diagnosis?
2. What is the allergen?
3. What percentage of the North American population has been sensitized to this allergen?

## Answers

1. Acute allergic contact dermatitis (poison ivy).
2. Pentadecylcatechols contained in the urushiol oleoresin are the main sensitizers.
3. Patch testing reveals that approximately 50% of the North American population has been sensitized to poison ivy.

Provided by Dr. Scott R.A. Walsh, Toronto, Ontario

## Share your photos and diagnoses with us!

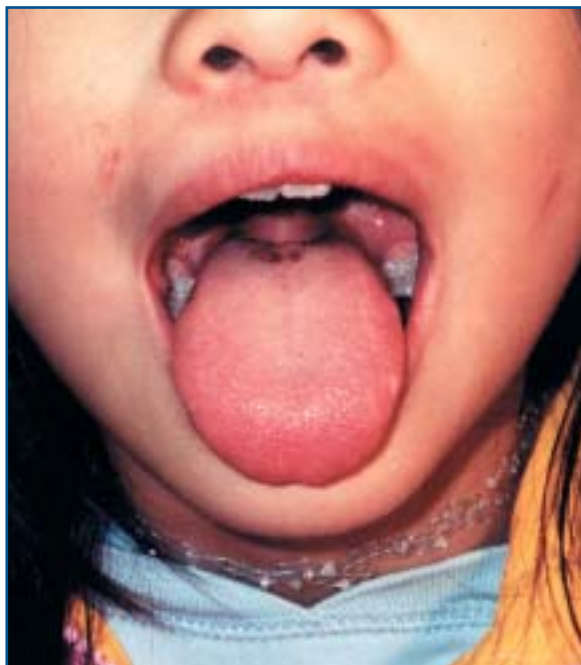
Do you have a photo diagnosis? Send us your photo and a brief text explaining the presentation of the illness, your diagnosis and treatment, and receive \$25 per item if it is published.

*The Canadian Journal of Diagnosis*

955, boul. St. Jean, suite 306,  
Pointe-Claire (Quebec) H9R 5K3

E-mail: [diagnosis@sta.ca](mailto:diagnosis@sta.ca)

Fax: (514) 695-8554



## Case 2

An eight-year-old girl was noted to have several reddish nodules on the posterior aspect of her tongue.

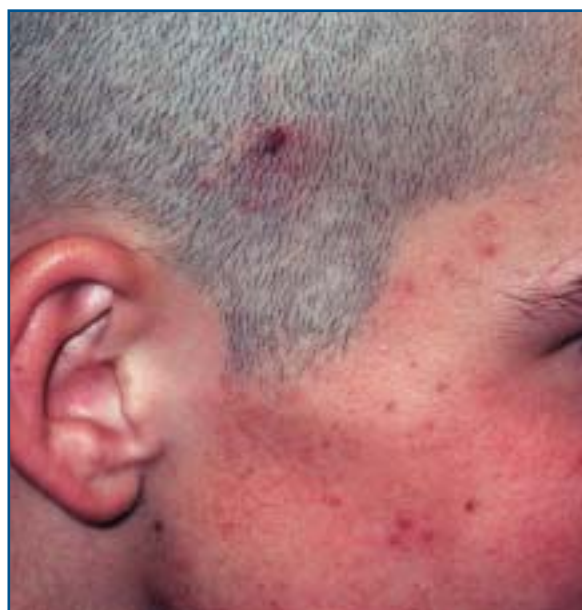### Questions

1. What is the diagnosis?
2. What are the potential complications?

### Answers

1. Lingual hemangioma.
2. Potential complications include hemorrhage, infection, ulceration, and trapping of platelets if the hemangioma is large enough.

Provided by Dr. Alexander K.C. Leung and Dr. Justine H.S. Fong, Calgary, Alberta.



## Case 3

An 18-year-old man was noted to have a soft, rapidly growing, red mass on the right side of the scalp. The mass bled easily.

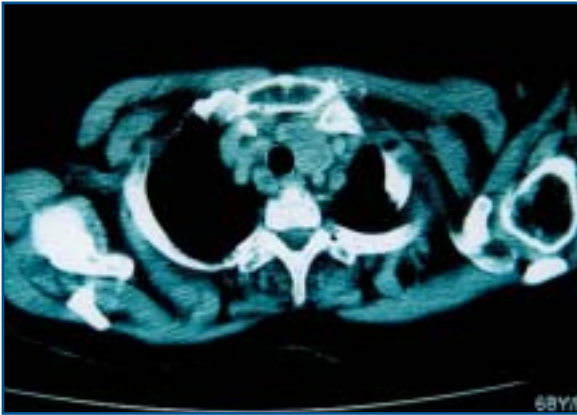
### Questions

1. What is the diagnosis?
2. What is the treatment?

### Answers

1. Granuloma pyogenicum.
2. Granuloma pyogenicum can be removed by excision or electrodesiccation.

Provided by Dr. Alexander K.C. Leung and Dr. Alexander G. Leong, Calgary, Alberta.



### Case 4

A computed tomography scan of the chest was ordered for a 67-year-old woman to assess her left lung nodule.

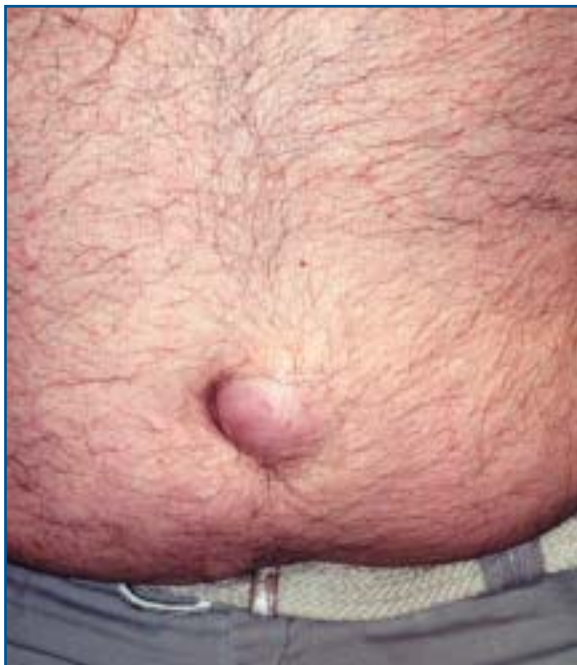#### Question

1. What does the scan show?

#### Answer

1. The scan shows enlargement of the thyroid, particularly the left lobe, with mediastinal extension. A multinodular goiter is suspected.

Provided by Dr. Jerzy Pawlak, Winnipeg, Manitoba.



### Case 5

A 35-year-old man was concerned about a mass protruding from his umbilical area.

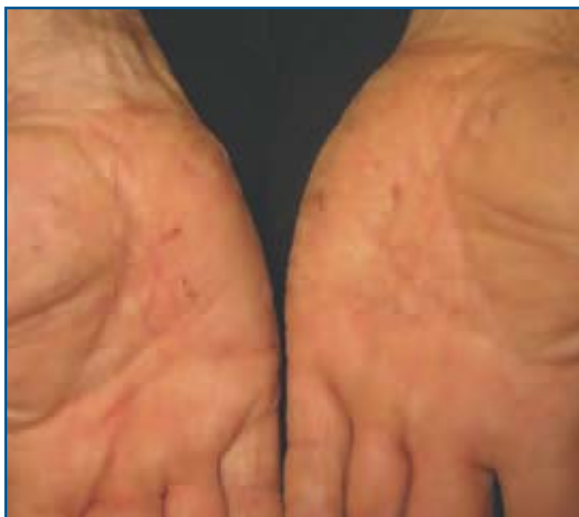#### Questions

1. What is the diagnosis?
2. What is the significance?

#### Answers

1. Paraumbilical hernia.
2. A paraumbilical hernia does not protrude through the umbilical scar. Rather, it protrudes just above or below the umbilicus. A paraumbilical hernia poses a risk for strangulation

Provided by Dr. Alexander K.C. Leung and Dr. Justine H.S. Fong, Calgary, Alberta.



## Case 6

A 44-year-old male auto mechanic presented with xerosis and cracking of his hands. These symptoms had been present for the past three years. He recalled having childhood eczema, but thought he had outgrown it. He was otherwise healthy.

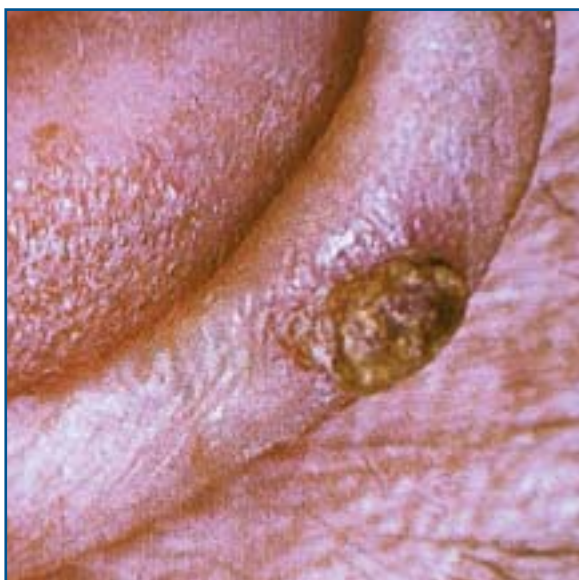## Questions

1. What is your diagnosis?
2. What puts someone at risk for this condition?

## Answers

1. Hand dermatitis
2. Risk factors include a childhood history of atopy and occupations that aggravate this underlying predisposition. Hand dermatitis is particularly common in occupations involving cleaning, catering, metalwork, hairdressing, health-care and mechanical work.

Provided by Dr. Benjamin Barankin, Edmonton, Alberta.



## Case 7

An 85-year-old man has had this lesion on his ear for three years.

## Questions

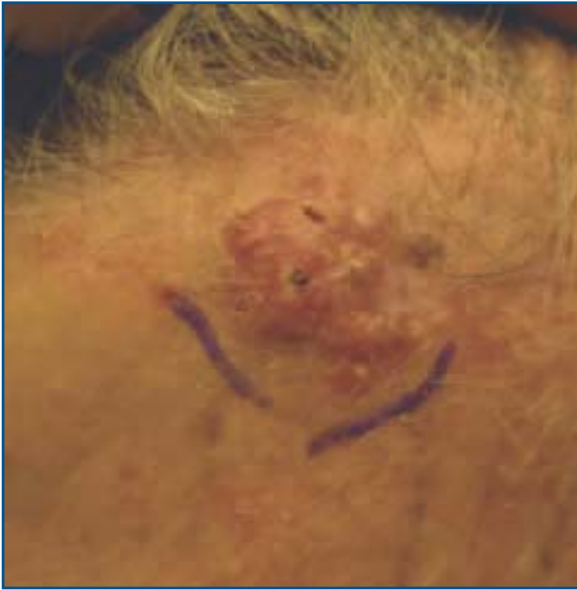1. What is the diagnosis?
2. What is the treatment?

## Answers

1. Actinic keratosis.
2. Actinic keratosis usually responds well to cryotherapy.

Provided by Dr. Rob Miller, Halifax, Nova Scotia.

Cont'd on page 50 →



### Case 8

An 84-year-old retired female farmer presented with multiple papules and plaques on her scalp, neck, and back of unknown duration. They were asymptomatic. She was otherwise healthy and never saw any doctors.

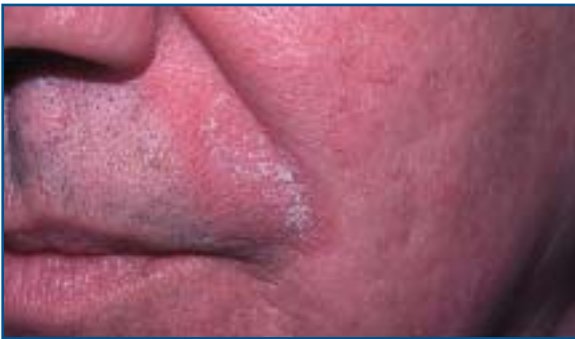#### Questions

1. What is your diagnosis?
2. How common is this condition?
3. What puts someone at risk for this condition?

#### Answers

1. Basal cell carcinoma (BCC).
2. BCC is the most common cancer in humans. The estimated lifetime risk of BCC in caucasians is approximately 35% in men and 25% in women.
3. Years of unprotected sun exposure and caucasian fair skin are the most common risk factors.

Provided by Dr. Benjamin Barankin, Edmonton, Alberta.




### Case 9

A 55-year-old man had a persistent rash in the nasolabial fold. He also had involvement of the scalp and eyebrows.

#### Question

1. What is the diagnosis?

#### Answer

1. Seborrheic dermatitis. 

Provided by Dr. Rob Miller, Halifax, Nova Scotia.