



A Cancer Scare

Benjamin Barankin, MD

A 53-year-old man presented with a long history of an asymptomatic purple papule on his left lower lip (Figure 1). He is a smoker and wonders whether he might have lip cancer.

1. What is the most likely diagnosis?

- a) Lichen planus
- b) Kaposi's sarcoma
- c) Venous lake
- d) Pigmented basal cell carcinoma
- e) Melanoma

2. What is the main concern with this purple papule?

- a) A sign of chronic sun exposure
- b) Local spread
- c) Metastases
- d) Suggests that patient may be hepatitis C-positive
- e) Suggests that patient may be HIV-positive

3. How could you treat this purple papule?

- a) Laser
- b) Cryotherapy
- c) Electrodesiccation
- d) Excision
- e) All of the above

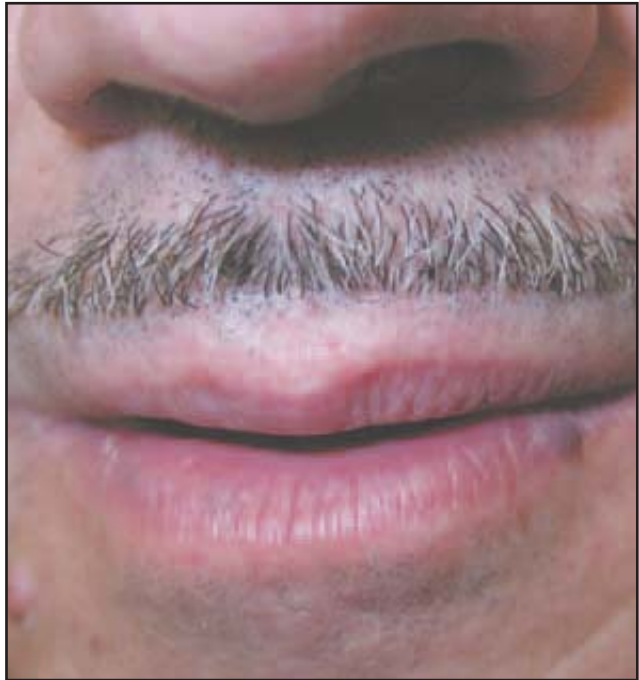


Figure 1. A purple papule on the lower left side of the lip.

Dr. Barankin is a dermatology resident, University of Alberta, Edmonton, Alberta.

"Case in Point" is a series of interesting cases and diagnoses so general practitioners can sharpen their skills. Submissions and feedback can be sent to diagnosis@sta.ca.

Answers: 1-c ; 2-a; 3-e