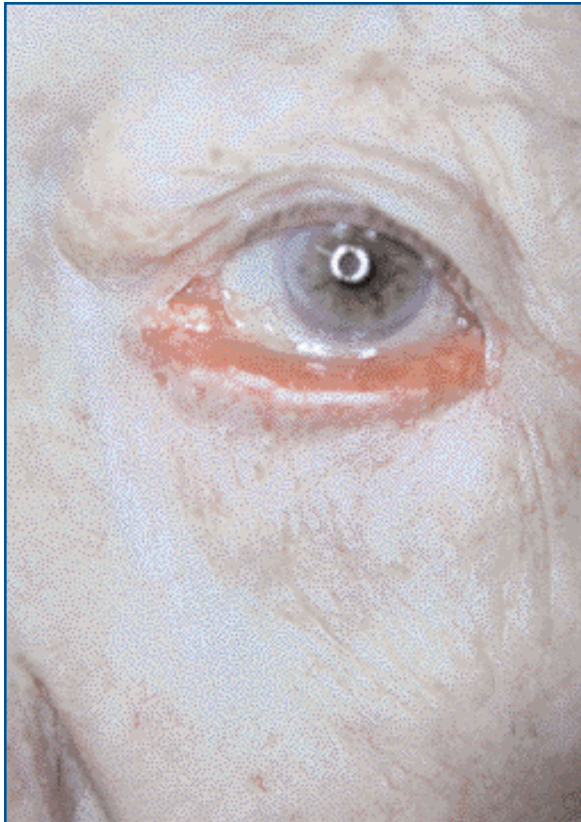



*Illustrated quizzes on  
problems seen in everyday practice*



## Case 1

A 77-year-old man presented with complaints of tearing, ocular irritation, redness, and eyelid matting on the left eye.

## Questions

1. What is the diagnosis?
2. What is the cause?

## Answers

1. Ectropion.
2. The most common cause of ectropion is an acquired involutional ectropion secondary to aging changes. Other causes of acquired ectropion are facial paralysis and cicatricial disease, as well as mechanical causes, such as eyelid tumours.

Provided by Dr. Jerzy Pawlak, Winnipeg, Manitoba.

*More photos on page 44* →

## Share your photos and diagnoses with us!

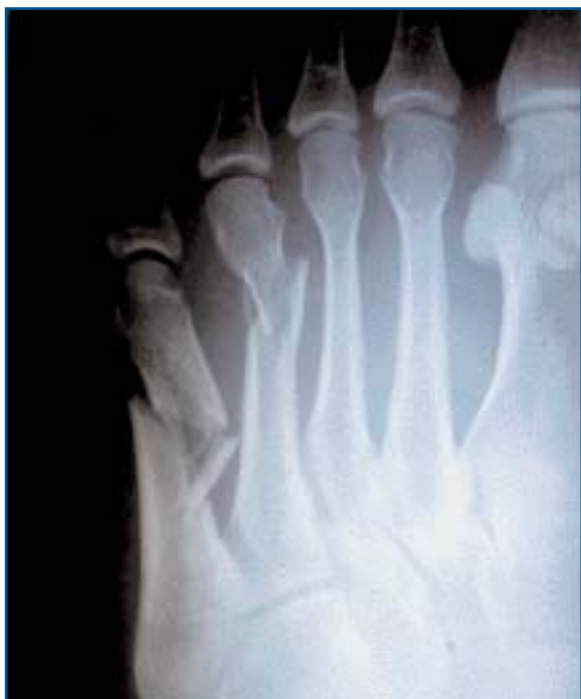Do you have a photo diagnosis? Send us your photo and a brief text explaining the presentation of the illness, your diagnosis and treatment, and receive \$25 per item if it is published.

*The Canadian Journal of Diagnosis*

955, boul. St. Jean, suite 306,  
Pointe-Claire (Quebec) H9R 5K3

E-mail: [diagnosis@sta.ca](mailto:diagnosis@sta.ca)

Fax: (514) 695-8554



### Case 2

A 32-year-old man presented with a swollen, tender left foot after contusion. An X-ray of the foot was performed.

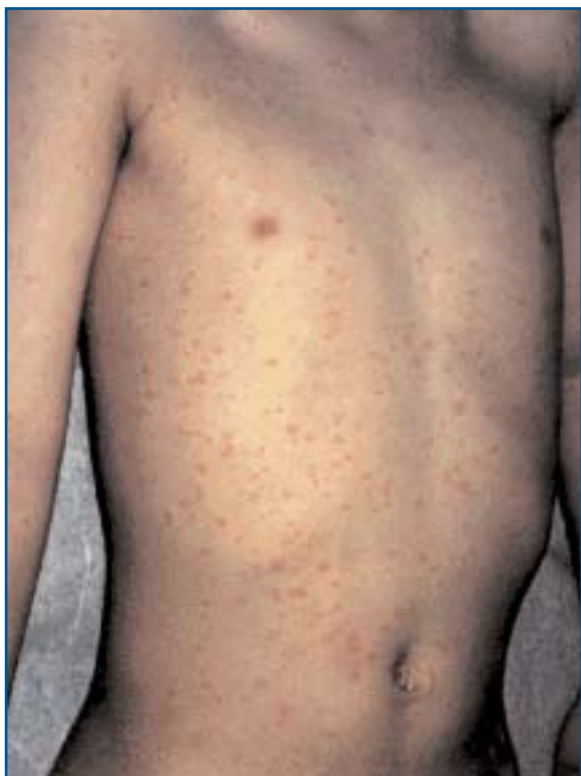#### Question

1. What does the X-ray show?

#### Answer

1. There is a comminuted fracture through the distal shaft of the fourth metatarsal with very slight medial displacement. There is also a comminuted fracture through the mid to distal shaft of the fifth metatarsal with medial displacement of the main distal fragment by half the width of the shaft.

Provided by Dr. Jerzy Pawlak and Dr. T. Krocak, Winnipeg, Manitoba.



### Case 3

A five-year-old boy presented with a fever of 39.4 C and an earache on the left side. On exam, the left tympanic membrane was erythematous. Ampicillin was prescribed and the child broke out with a rash 24 hours later.

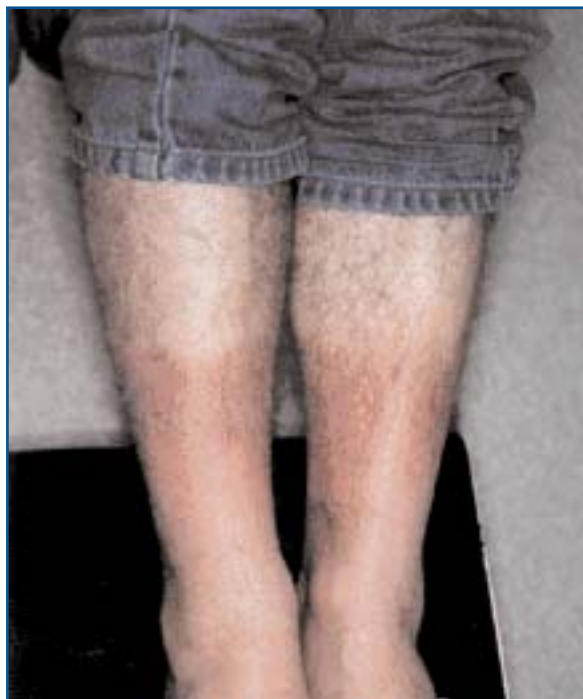#### Questions

1. What is the diagnosis?
2. What is the significance?

#### Answers

1. Ampicillin-induced eruption.
2. The incidence of eruption in patients treated with ampicillin is about 2.5%. However, the incidence of eruption in patients with infectious mononucleosis who receive ampicillin at the same time is over 70%.

Provided by Dr. Alexander K.C. Leung and Dr. Justine H.S. Fong, Calgary, Alberta.



## Case 4

A 74-year-old woman presented to the clinic concerned about a pruritic rash on both her ankles after wearing new socks.

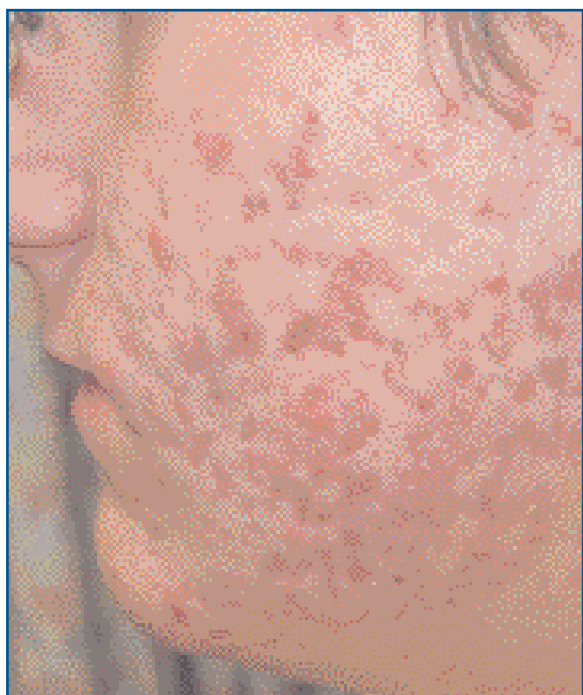### Questions

1. What is the diagnosis?
2. What type of hypersensitivity reaction is it?

### Answers

1. Allergic contact dermatitis.
2. Allergic contact dermatitis is a type IV hypersensitivity reaction affecting previously sensitized individuals.

Provided by Dr. Jerzy Pawlak, Winnipeg, Manitoba.



## Case 5

This 16-year-old young man presented with bright red nodules and cysts on his face present for the last eight months.

### Questions

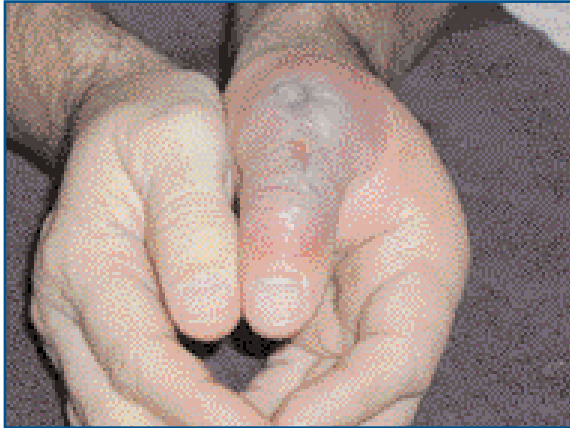1. What is the diagnosis?
2. What is the treatment?

### Answers

1. Nodulocystic acne.
2. Isotretinoin, 1 mg/kg, for a total cumulative dose of 120 mg/kg to 150 mg/kg.

Provided by Dr. Benjamin Barankin, Edmonton, Alberta.

Cont'd on page 48 →



### Case 6

This 42-year-old man presented with a painful, dark purple demarcation with a blue-grey hue on his thumb. He recalls cleaning up his cottage and being bitten by something while reaching behind the lavatory.

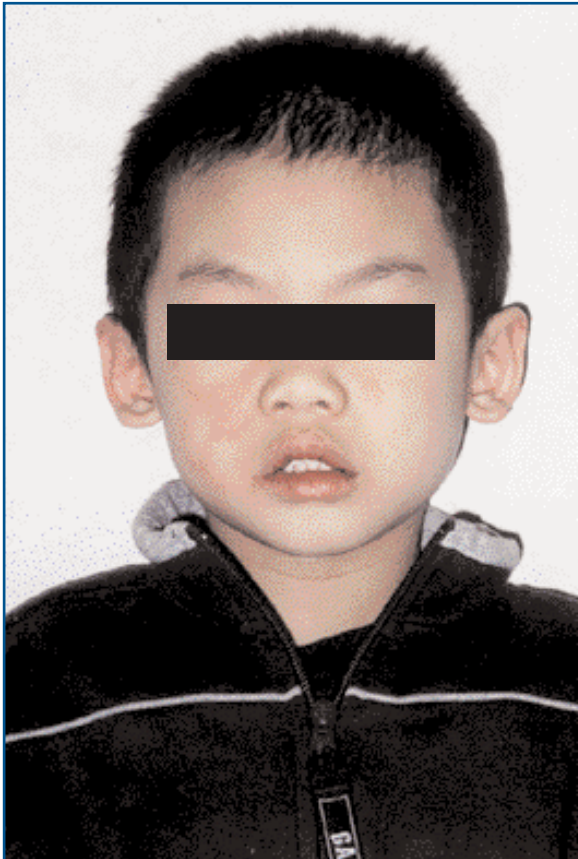
#### Questions

1. What is the diagnosis?
2. What is the treatment?

#### Answers

1. Brown recluse spider bite.
2. Conservative measures can be used, including cold compresses and analgesics. No systemic agents have been proven to prevent necrosis, and most wounds heal nicely within two to three months.

Provided by Dr. Benjamin Barankin, Edmonton, Alberta.



### Case 7

A four-year-old boy presented with fever (temperature 41 C) for four days. On exam, he was noted to have oropharyngeal erythema, erythema and swelling of the hands and feet, and bilateral cervical lymphadenopathy.

#### Questions

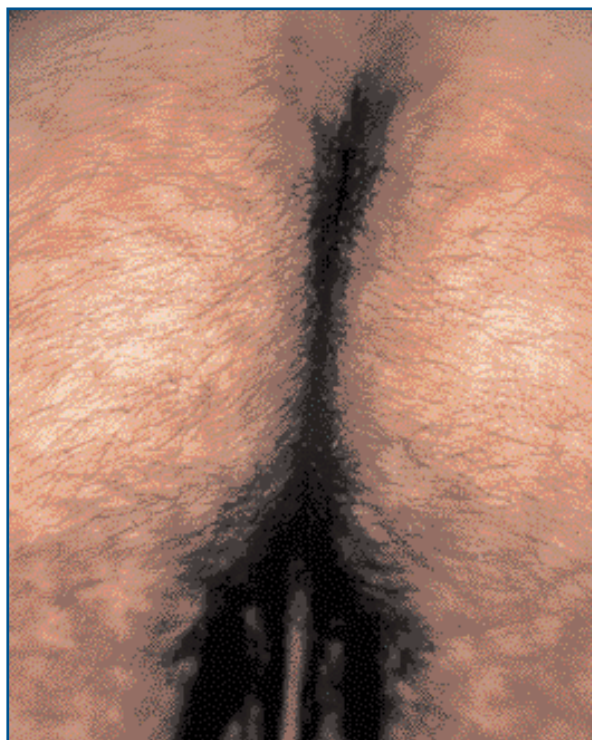1. What is the diagnosis?
2. What is the significance?
3. What is the treatment?

#### Answers

1. Kawasaki disease.
2. Kawasaki disease may be complicated by myocarditis, pericarditis, and coronary artery aneurysm.
3. The patient was treated with oral salicylates and intravenous gamma globulin. He had an uneventful recovery. An echocardiogram was normal.

Provided by Dr. Alexander K.C. Leung and Dr. Justin H.S. Fong, Calgary, Alberta.





## Case 8

This patient presented with an unusual eruption on his buttocks.

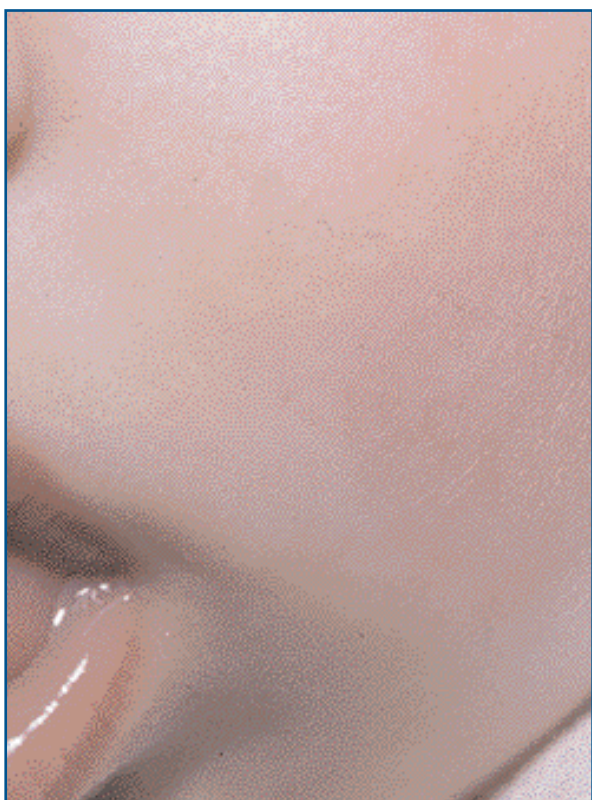### Questions

1. What is the diagnosis?
2. What is the cause?

### Answers

1. Erythema Ab Igne.
2. This patient has been applying a heating blanket to his buttocks on a daily and nightly basis to help him relieve his hip pain. Subsequently, he developed this characteristic, vascular-related, heat-induced eruption. Once the heating blanket was discontinued, the eruption gradually resolved over a period of several months.

Provided by Dr. Rob Miller, Halifax, Nova Scotia.



## Case 9

This toddler developed a slightly indurated plaque for a few days after eating a popsicle.

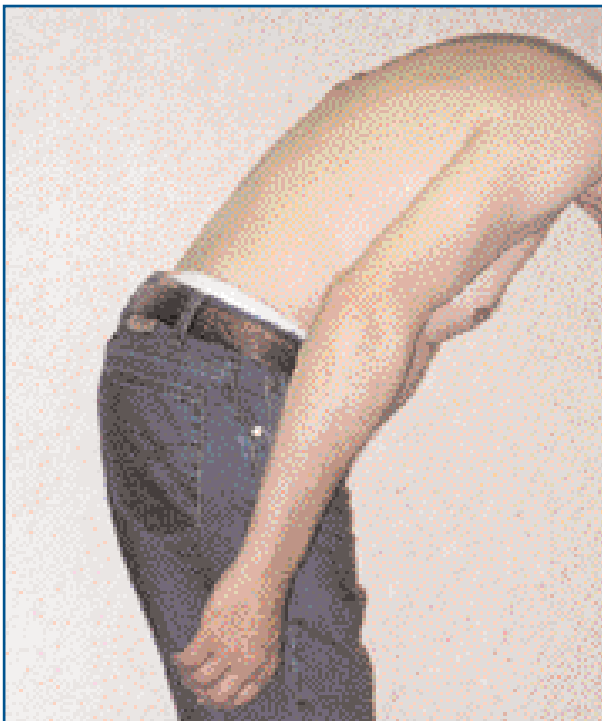
### Question

1. What is the diagnosis?

### Answer

1. Cold panniculitis. This type of cold-induced fat injury is typically seen in young infants and toddlers as a result of localized cold exposure. With time, this rash will resolve on its own.

Provided by Dr. Rob Miller, Halifax, Nova Scotia.



### Case10

A 58-year-old man has had chronic lower back pain and stiffness for the past 30 years.

### Questions

1. What is the diagnosis?
2. What is the significance?

### Answers

1. Ankylosing spondylitis.
2. Patients with ankylosing spondylitis may have simultaneous onset of peripheral arthritis. They are also at risk for atlantoaxial subluxation, spinal cord compression, aortic valve incompetence, anterior uveitis, and cauda equina syndrome. **Dx**

Provided by Dr. Alexander K.C. Leung and Dr. Justine H.S. Fong, Calgary, Alberta.

