It All Depends on Your Point of View

Keith J.C. Finnie, MB, ChB

Vignette

A 37-year-old man presents complaining of severe chest pain which began two hours earlier. He says that, as a child, he was told he had a heart problem. His electrocardiogram (ECG) on initial presentation is shown in Figure 1.

Questions

1. **What is the clinical diagnosis?**
2. **What was the heart problem in childhood?**

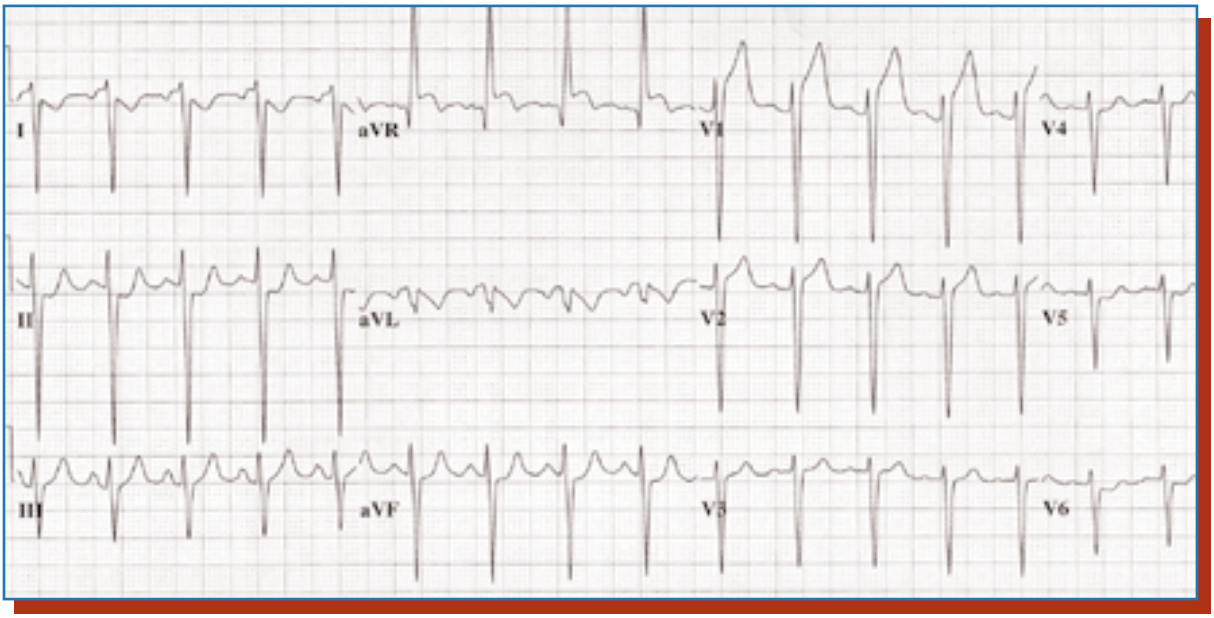

Figure 1. ECG on initial presentation.

Dr. Finnie is a professor of medicine, University of Western Ontario, and site chief of cardiology, London Health Sciences Centre, Victoria Campus, South Street, London, Ontario.

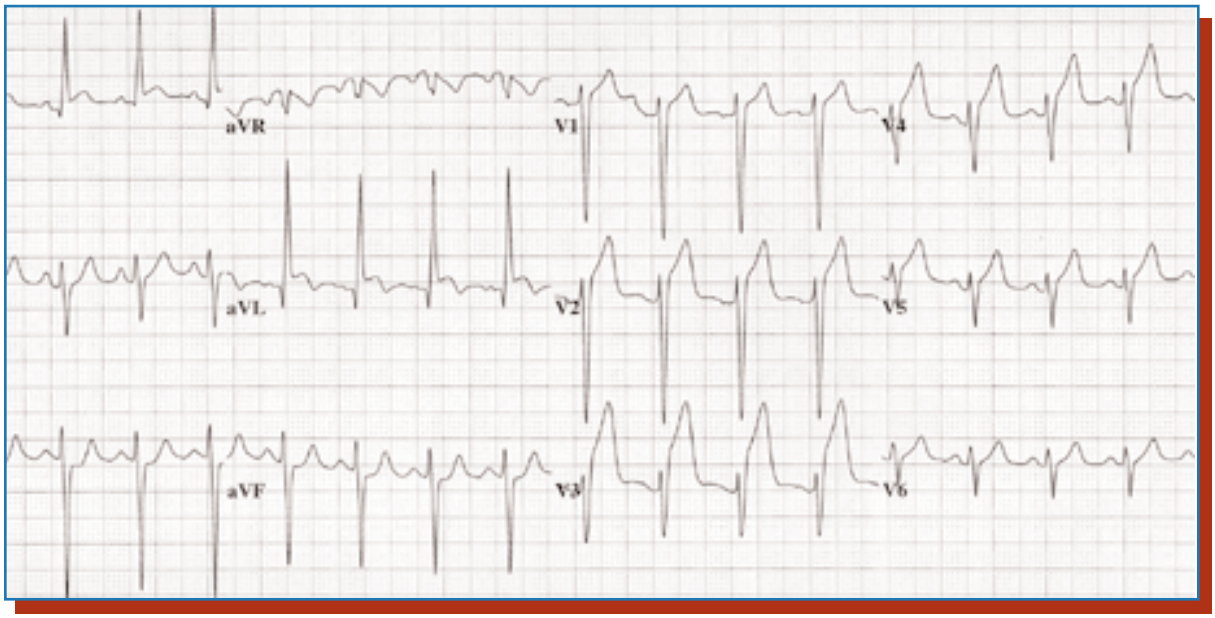

Figure 2. ECG with arm electrodes reversed.

Answers

1. There are several abnormalities on the initial ECG. The rhythm is sinus tachycardia at 108 beats per minute, and the high QRS voltages are suggestive of left ventricular hypertrophy. There appears to be unusual superior deviation of the QRS axis and leads 1 and aVL show negative, rather than the expected positive, polarity. The QRS in aVR is positive, rather than negative, and this lead also shows ST segment elevation. Normally, this would indicate acute epicardial injury, but aVR is usually oriented towards the cavity of the left ventricle.

Finally, there is ST segment elevation in V_1 and loss of the expected progressive increase in R wave amplitude across the precordial leads.

2. The clue to the correct diagnosis lies in recognizing that the P waves in leads 1 and aVL are inverted, and that aVL looks more like a normal aVR lead. This is the electrocardiographic appearance when the right and left arm electrodes are reversed, or when the patient has dextrocardia. In this case, the loss of precordial R wave progression (the electrodes are getting farther away from the left ventricle) suggests dextrocardia.

With this in mind, visualize lead 1 as inverted and aVR as aVL. Both leads show ST segment elevation in keeping with a high lateral current of injury. This is still not the complete picture, however. Because the precordial leads are effectively "right-sided," the true extent of the acute injury can only be appreciated by repeating the ECG with the right and left arm electrodes reversed (to correct the limb leads), and with the precordial leads on the right side of the chest to reflect left ventricular forces (Figure 2). With these anatomic "corrections," the ECG picture of an acute anterolateral myocardial infarction is immediately apparent. Dx