


# Photo Diagnosis

*An illustrated quiz on  
problems seen in everyday practice*



## Case 1

A 48-year-old woman, treated one year ago with radioactive iodine for Graves' disease (presently euthyroid), presented with left eye pain, prominence, and increased lacrimation.

## Questions

1. What is the diagnosis?
2. Can it happen one year after treatment?
3. Can it affect one eye?

## Answers

1. Graves' ophthalmopathy (left eye proptosis, 21 mm by Hertel ophthalmometer [normally < 18]).
2. Yes, it can happen even years after treatment.
3. Frequently, it can be unilateral or asymmetrical. A magnetic resonance image of the orbits in this woman was negative for left retro-orbital tumour.

Provided by Dr. M. Usman Chaudhry, Moncton, New Brunswick.

## Share your photos and diagnoses with us!

Do you have a photo diagnosis? Send us your photo and a brief text explaining the presentation of the illness, your diagnosis and treatment, and receive \$25 per item if it is published.

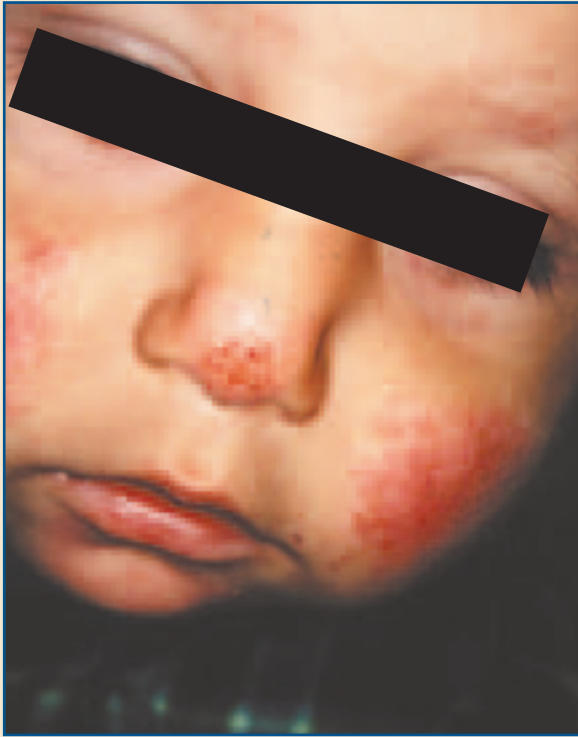*The Canadian Journal of Diagnosis*

955, boul. St. Jean, suite 306,

Pointe-Claire (Quebec) H9R 5K3

E-mail: [diagnosis@sta.ca](mailto:diagnosis@sta.ca)

Fax: (514) 695-8554



## Case 2

A 17-month-old infant presented with a history of pruritic, dry patches on the face, and extensor surfaces of his extremities since the age of three months.

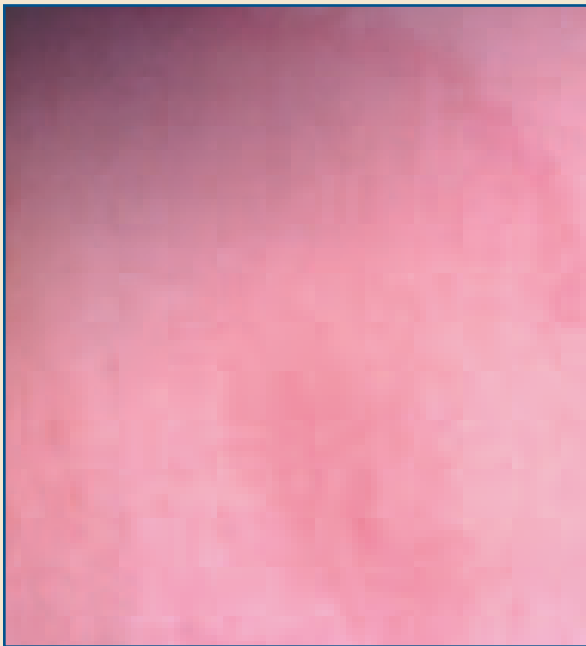
### Questions

1. What is the differential diagnosis?
2. What is the treatment?
3. What is the significance?

### Answers

1. Atopic dermatitis.
2. Hydrocortisone ointment or cream (1%), with emollient, should be applied twice daily, with recommendation to avoid contact irritants.
3. Atopic dermatitis is an acute or subacute, but usually chronic, pruritic inflammation of the epidermis and dermis. It often occurs in association with personal or family history of hay fever, asthma, or allergic rhinitis.

Provided by Dr. Jerzy Pawlak, Winnipeg, Manitoba.



## Case 3

This patient presented with a rash, which began a week after being bitten by an insect.

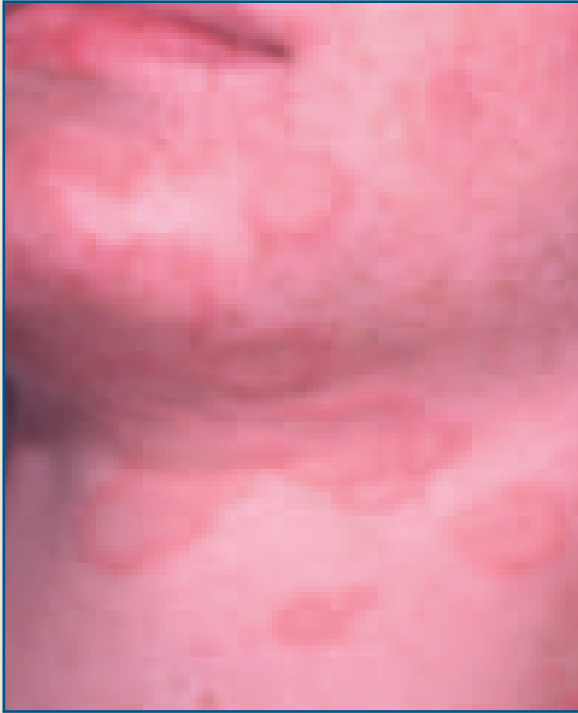### Questions

1. What is the diagnosis?
2. What is the treatment?

### Answers

1. Erythema chronicum migrans (Lyme disease).
2. Doxycycline, 100 mg to 200 mg per day for 14 days.

Provided by Dr. Rob Miller, Halifax, Nova Scotia.



### Case 4

This 25-year-old woman developed a rash five days after having an outbreak of a cold sore on her lips. She had a similar reaction one year ago.

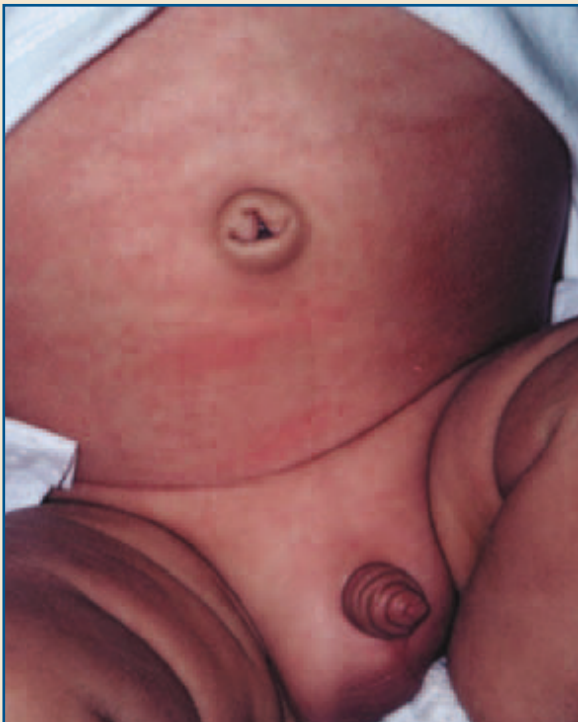#### Questions

1. What is the diagnosis?
2. What is the cause?

#### Answers

1. Erythema multiforme (EM).
2. EM has many underlying causes. While many cases are idiopathic in nature, EM may be precipitated by infectious agents, such as herpes simplex virus. Another infectious agent is mycoplasma.

Provided by Dr. Rob Miller, Halifax, Nova Scotia.



### Case 5

The mother of this two-year-old boy is concerned about the look of the umbilicus of the child.

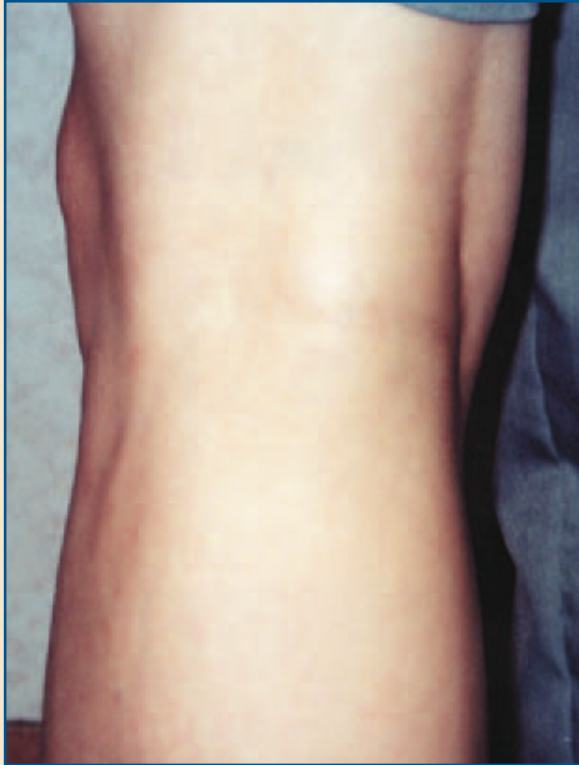#### Questions

1. What is the diagnosis?
2. What is the significance?

#### Answers

1. Cutis navel.
2. Cutis naval is a harmless condition and no treatment is necessary.

Provided by Dr. Alexander K.C. Leung and Dr. Justine H.S. Fong, Calgary, Alberta.



## Case 6

A 50-year-old man presented with a cystic mass in the left upper popliteal fossa for six months. The mass was not pulsatile. He had a long-standing history of multiple joint pain.

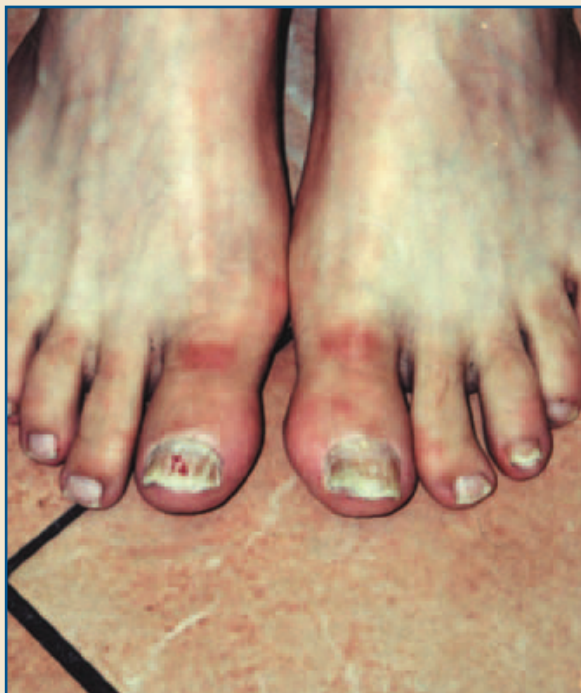### Questions

1. What is the diagnosis?
2. What is the significance?

### Answers

1. Baker's cyst.
2. Baker's cyst is caused by herniation of the synovium of the knee joint into the popliteal space. Baker's cyst appears in elderly patients with long-standing osteoarthritis and in younger patients with rheumatoid arthritis.

Provided by Dr. Alexander K.C. Leung and Dr. Justine H.S. Fong, Calgary, Alberta.



## Case 7

A 28-year-old man presented with whitish discoloration of the nails.

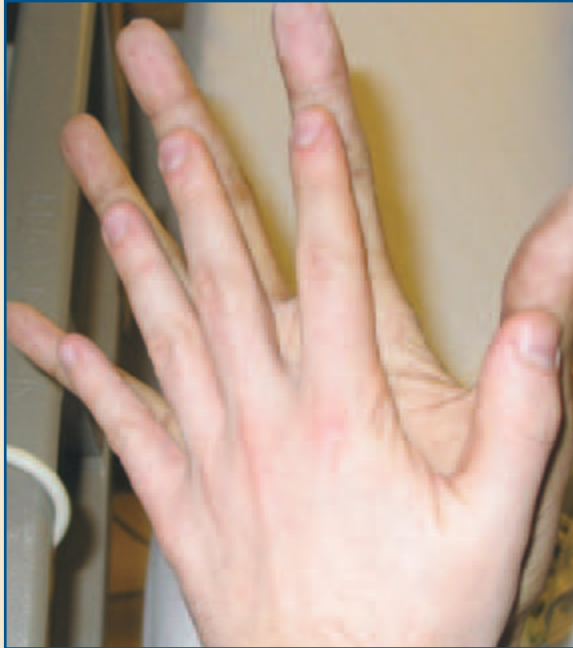### Questions

1. What is the diagnosis?
2. What is the treatment?

### Answers

1. Onychomycosis.
2. Onychomycosis is best treated with oral antifungal agents (terbinafine or itraconazole) in combination with trimming of the affected nails.

Provided by Dr. Alexander K.C. Leung and Dr. Alexander G. Leong, Calgary, Alberta.



### Case 8

This 42-year-old man is very tall, thin, and has large hands and pectus excavatum.

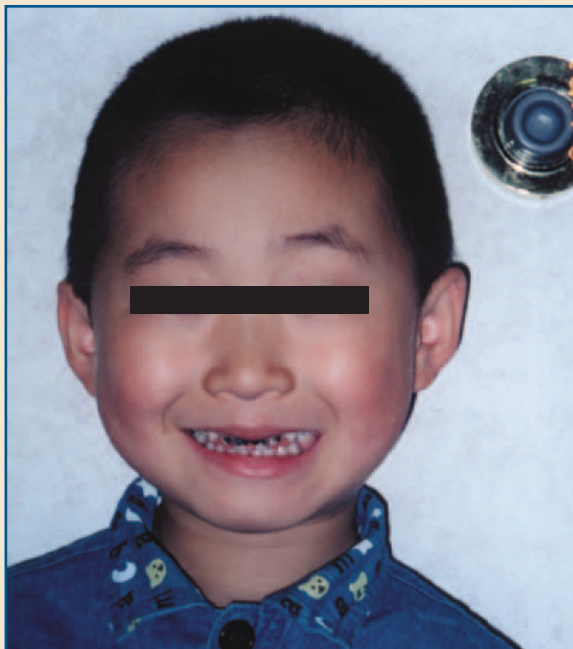#### Question

1. What is the diagnosis?

#### Answer

1. Marfan syndrome.

Provided by Dr. Benjamin Barankin, Edmonton, Alberta.




### Case 9

A three-year-old boy has caries that mainly affect his upper incisors.

#### Questions

1. What is the diagnosis?
2. What is the cause?

#### Answers

1. Nursing bottle syndrome.
2. Nursing bottle syndrome results from prolonged exposure to sucrose-enriched liquids during sleep. 

Provided by Dr. Alexander K.C. Leung and Dr. Justine H.S. Fong, Calgary, Alberta.

**FULL** on **ALL**  
**COVERAGE** Provincial Formularies

Once-a-day  
**REMERON**  
Because your patient doesn't have time to wait.

\*BC, AB, SK, MB, ON, QC, NS, NB, NFLD, and PEI.  
REMERON is a registered trademark of Organon Canada Ltd.