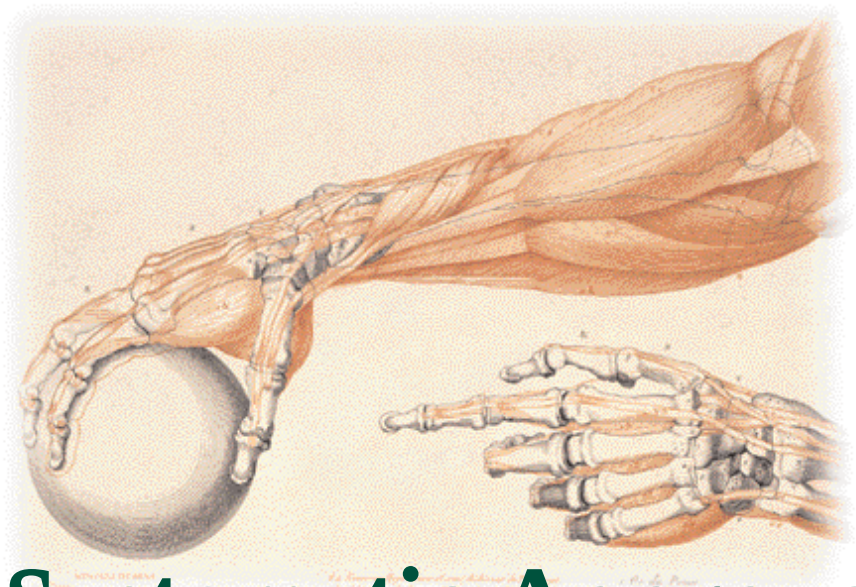

A Systematic Approach To A Painful Wrist

Although wrist injuries are not life threatening, they are of great importance in terms of how they can affect daily functioning. Without an accurate diagnosis, treatment of wrist pain becomes increasingly difficult.

By Robert Wang, BSc; Jeremy Reed, MD; James Leone, MD; Mohit Bhandari, MD, MSc; and Jaydeep K. Moro, MD, FRCSC

Wrist pain is a serious problem in terms of morbidity, since it often leads to functional disability. The causes of wrist pain are diverse and present as difficult diagnostic and therapeutic challenges. It is important, therefore, to have a clear approach when assessing wrist pain in order to make consistently accurate diagnoses. The purpose of this article is to provide a systematic approach in evaluating adult wrist pain.

Anatomy of the Wrist

The bony anatomy of the wrist consists of the distal radius, distal ulna and the carpal bones. The distal radioulnar, radiocarpal and ulnocarpal joints form the proximal border of the wrist. The eight carpal bones demarcate its distal border (Figure 1).

The ligaments that stabilize the wrist joint are grouped into three regions. First, the triangular fibrocartilage complex (TFCC) attaches the distal radius, lunate and triquetrum to the distal ulna[1] (Figure 2).

Second, the interosseous intrinsic ligaments which connect the proximal and distal row of the carpal bones. Third, the extrinsic ligaments extend from the radius and ulna distally across the carpal rows. All three groups of ligaments exist on both the dorsal and volar aspects of the wrist.

The main artery that supplies the wrist joint is the radial artery. Three arches branching from the radial artery supply the distal radius, distal ulna and the carpal bones. The scaphoid receives retrograde blood supply; that is, it is nourished by blood that flows from a distal to proximal direction. Any injury that compromises the vessel supplying the scaphoid can result, therefore, in avascular necrosis.[2]

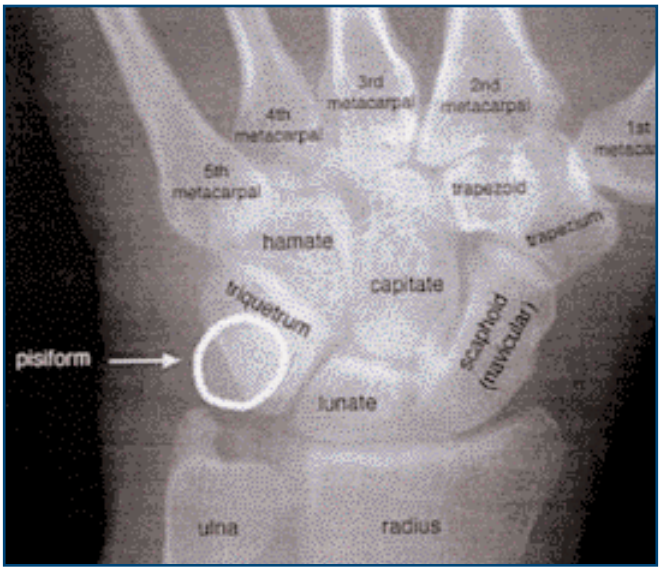

Figure 1. Bony anatomy of the wrist joint. Adapted from www.scar.rad.washington.edu/RadAnat/WristPA-Labelled.html.

Biomechanics of the Wrist

The proximal capitate constitutes the center of rotation for most wrist movements. Flexion and extension occur primarily because of motion at the radiocarpal joint. Radial-to-ulnar deviation requires motion through the radiocarpal and intercarpal joints. On the other hand, only intercarpal joint motion is responsible for ulnar-to-radial deviation. The proximal carpal row functions to connect the forearm to the hand, with the scaphoid acting as the wrist stabilizer.[3]

The three-column theory of the wrist is used for understanding force transmission through the wrist with various mechanisms of injury.[1,4] The central (force-bearing) column consists of the distal articular surface of the radius, the lunate and the capitate. The radial column is composed of the radius,

Mr. Wang is research student, division of orthopedic surgery, McMaster University, Hamilton, Ontario.

Dr. Leone is resident, division of orthopedic surgery, McMaster University, Hamilton, Ontario.

Dr. Bhandari is research fellow, McMaster University, Hamilton, Ontario.

Dr. Moro is consultant, division of orthopedic surgery, St. Joseph's Hospital, Hamilton, Ontario.

Dr. Reed is resident, division of orthopedic surgery, University of Calgary, Calgary, Alberta.

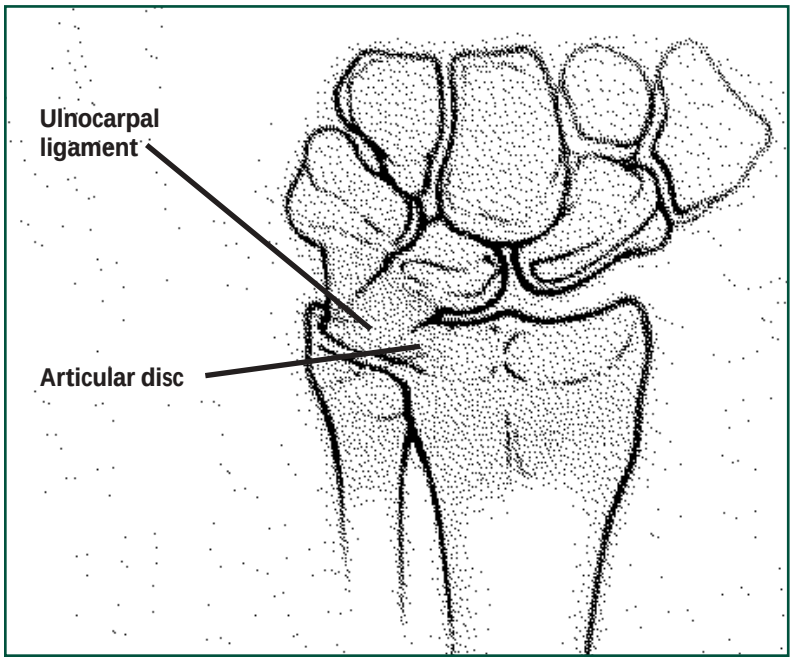

Figure 2. Triangular fibrocartilage complex.
Adapted from Reference 1.

scaphoid, trapezium, trapezoid and thumb carpometacarpal joint. The ulnar (control) column includes the TFCC, hamate, triquetrum and the articulation of the carpometacarpal joints of the fourth and fifth phalanges.

Establishing a Diagnosis

History

The causes of wrist pain are diverse. It is useful to first establish whether the pain is due to a traumatic or non-traumatic etiology. In the case of trauma, ligament rupture/tear, tendon injury, and fracture(s) need to be investigated.[5] Inquiring about the mechanism of injury is the first step in localizing the affected part of the wrist. A fall on the outstretched hand is a common mechanism of injury. When the hand strikes the ground, a vertical force with variable lateral and dorsal components is transmitted through the carpal bones to the lower end of the radius. This commonly results in fracture of the distal radius.[6] Furthermore, since the scaphoid acts as a hinge in stabilizing the wrist joint, the direction of force transmitted through a fall on the outstretched hand makes the scaphoid prone to injury.

Wrist trauma may not always have a clear history. Patients sometimes have difficulty relating the wrist pain to a specific traumatic episode. In such situations, it is important to inquire about the patient's occupation. Repetitive motions across the wrist joint can cause pain, without any incident or trauma.[7] Patients who work in construction and are exposed to vibrating instruments, such as jackhammers, are more prone to wrist pain directly related to repetitive stress.[8] Such mechanisms of injury may result in a fracture/dislocation, however, tendonitis/tenosynovitis also is a common cause of wrist pain caused by repetitive motion.

Non-traumatic etiologies of wrist pain can vary. It is useful to characterize the pain and inquire about systemic symptoms. Abrupt onset of pain can indicate infection, arthritis or osteonecrosis. Gradual onset of symptoms are more characteristic of tenosynovitis, nerve entrapment syndromes or arthritis.

A person's age and sex also help to focus the diagnosis. Younger patients (less than 40 years) are more prone to post-traumatic carpal injuries, whereas the older population is more susceptible to systemic diseases and degenerative processes that involve the wrist joint. Osteoarthritis and rheumatoid arthritis seem to affect women more frequently than men.[4] Refer to Tables 1 and 2 for the causes

of wrist pain and a summary of pertinent points to consider when taking a history.

Physical Examination

The wrist exam should be conducted in a systematic order. On initial inspection, a circumferential examination of the skin around the wrist is important to rule out an open fracture. The shape of the deformity and extent of the swelling are clues to the underlying injury.

The classic "dinner fork" deformity is seen in an apex volar fracture of the distal radius (Colles' fracture), and prominence of the ulnar head can be observed in separation of the distal radioulnar joint (DRUJ).[9,10] It also is important to observe for muscle atrophy by comparing bilateral symmetry in muscle bulk. Muscle wasting of thenar eminence is seen with median nerve compression. Neurologic status of the hand distal to the site of injury should be carefully assessed (Table 3).

The next step in the focused clinical exam is palpation of the wrist, beginning on the dorsal surface and progressing to the volar surface. Often, a routine wrist palpation is inadequate to elicit the symptoms described by the patient. In such circumstances, provocative tests are necessary to help pinpoint the specific anatomic structure(s) that is causing the pain.

Table 1

OUTLINE OF SOME CAUSES OF WRIST PAIN

Traumatic

- Fractures
- Fracture nonunion
- Subluxations/dislocations
- Ligament rupture or tear
- Tendon tear

Non-traumatic

- Arthritis
  - Degenerative
  - Septic
  - Inflammatory
  - Crystal
- Peripheral nerve entrapment
  - Carpal tunnel (median nerve)
  - Ulnar Nerve
  - Interosseous
- Tenosynovitis
- Avascular Necrosis
- Other: Osteomyelitis, neoplasm, referred pain from cervical spine and shoulder

Provocative Testing

Carpal bones and carpal joints. The scapho-trapezio-trapezoid joint can be palpated to assess for arthritis. With one hand the physician should stabilize the patient's scaphoid and trapezium, while using the other hand to manipulate the trapezoid in a grinding motion. If pain is elicited and is more severe than the non-affected side, arthritis is likely to exist. Tenderness in the anatomic snuffbox suggests a scaphoid fracture, however, it is non-specific. Pain in this region can also indicate radioscaphoid arthritis, radiocarpal synovitis or scapholunate ligament instability.[4]

The integrity of the scapholunate interosseous ligament should be assessed, as it is a structure prone to injury. The physician should stabilize the scaphoid to restrict its palmar flexion while moving the patient's wrist from ulnar to radial deviation.

In a wrist with a scapholunate interosseous ligament tear, the scaphoid will sublux dorsally as the wrist reaches maximum

Table 2
IMPORTANT POINTS TO CONSIDER ON HISTORY

Is the wrist pain due to trauma?

- If the wrist pain is due to an acute trauma, look for fractures and ligamentous injuries.
- The most common fractures due to a fall on the outstretched-hand are distal radial and scaphoid.
- The most common ligamentous injury is the scapholunate ligament.

What is the patient's occupation?

- Repetitive wrist motions can cause occult fractures, tenosynovitis and nerve entrapment syndromes (most commonly carpal tunnel syndrome).

Age of the patient

- In the absence of trauma, consider arthritis, neoplasm and referred pain in the older population.
- For younger patients, traumatic injury and overuse are more common.

Sex of the patient

- Systemic disease, such as rheumatoid arthritis, is more common in females.

Characterize the pain

- In the absence of an obvious etiology, carefully characterize the pain and consider further investigative tools to help reach a diagnosis.

radial deviation, and will produce dorsal wrist pain.[11] Tenderness with compression or manipulation of the pisiform may indicate pisotriquetral arthritis.[4] Pain on palpation of the hook of the hamate is suggestive of a fracture. The integrity of the lunatotriquetral interosseous ligament can be tested by the shear test or ballottement test.[12] The triquetrum is stabilized by applying palmar pressure at the pisiform and dorsal pressure over the triquetrum. The lunate is then manipulated against the triquetrum. Discomfort or excessive translation compared with the opposite wrist is a positive finding. Midcarpal instability produces a "catch-up clunk" that is heard when the wrist is moved in a radial-to-ulnar direction during axial loading.[4,8]

Ulnocarpal and distal radioulnar joints. Ulnocarpal abutment and TFCC tears are evaluated by ulnar deviation of the wrist, combined with axial loading. This maneuver should be performed with the patient's forearm in neutral, supine and prone positions.

Reproduction of the pain, combined with tenderness just distal to the ulnar styloid, is consistent with ulnocarpal abutment and/or TFCC tears.[3] The stability of the DRUJ is tested by manipulating the radius relative to the ulna. The maneuver should be performed with the patient's forearm in neutral, prone and supine positions.[3,4] DRUJ arthrosis can be evaluated by compressing the joint. Pain and crepitation are suggestive of arthritis.

Tenosynovitis (inflammation of the tendon sheath) causes pain during ulnar devia-

Table 3
NEUROLOGIC EXAMINATION OF THE HAND

Nerve/Modality	Sensory	Motor
Ulnar	Supplies sensation to the palmar and dorsal surfaces of the little finger and of the ulnar half of the ring finger. Sensation is best tested toward the tip of the little finger.	Test adduction (interosseous muscles) and abduction (abductor digiti minimi) of the little finger, adduction of the thumb (adductor pollicis), and abduction of the index finger (first dorsal interosseous) against resistance.
Median	Supplies sensation mainly to the radial side of the palm and the fingers. Sensation is best tested on the palmar aspect of the index finger.	Have the patient resist abduction of the thumb and note the tone of the thenar eminence. This tests the abductor pollicis brevis muscle.
Radial	Supplies sensation to the radial side of the dorsum of the hand. Sensation is best tested between the thumb and the index finger.	Test extension of the fingers at the MP joints against resistance. Flexion of the elbow against resistance with the forearm in neutral position tests the brachioradialis muscle, which is also supplied by the radial nerve.

tion, with the forearm moving between supination and pronation.[13]

Neuropathies also may cause wrist pain, with carpal tunnel syndrome being one of the most common presentations. This condition can be diagnosed based on history and positive Phalen's and Tinel's tests. Phalen's test is performed by flexing the patient's wrists to a 90-degree angle for 60 seconds.[5] A positive sign reproduces the symptoms. A positive Tinel's test reproduces the patient's symptoms by tapping along the median nerve at the wrist.

Radiologic Investigation

Routine radiographic views of the wrist include posterior-anterior (PA), lateral and oblique. Special views can be obtained to investigate specific conditions that are not easily identified on routine films.

PA view. In this view, it is important to examine the alignment of the carpal bones, the DRUJ and the soft tissues.

On a PA view of a normal wrist, each carpal joint space measures 1 mm to 2 mm.[1,3] Two smooth curves can be drawn to represent the normal alignment of the carpal bones. The proximal curve is formed by the proximal surfaces of the scaphoid, lunate and triquetrum. The distal curve is formed by the proximal surfaces of the capitate and hamate (Figure 3). Fractures involving the distal radius or the carpal bones can result in discontinuity of the arcs. Abnormal alignment and discontinuity of the arcs also can indicate ligamentous injury. Associated joint-space widening may be seen at the site of injury.

Neuropathies may cause wrist pain, with carpal tunnel syndrome being one of the most common presentations.

In a normal wrist, the DRUJ space measures 2 mm.[1,3] The positive and negative ulnar variance describes the extent to which the DRUJ is disrupted. Any traumatic type of injury can cause DRUJ separation. Positive

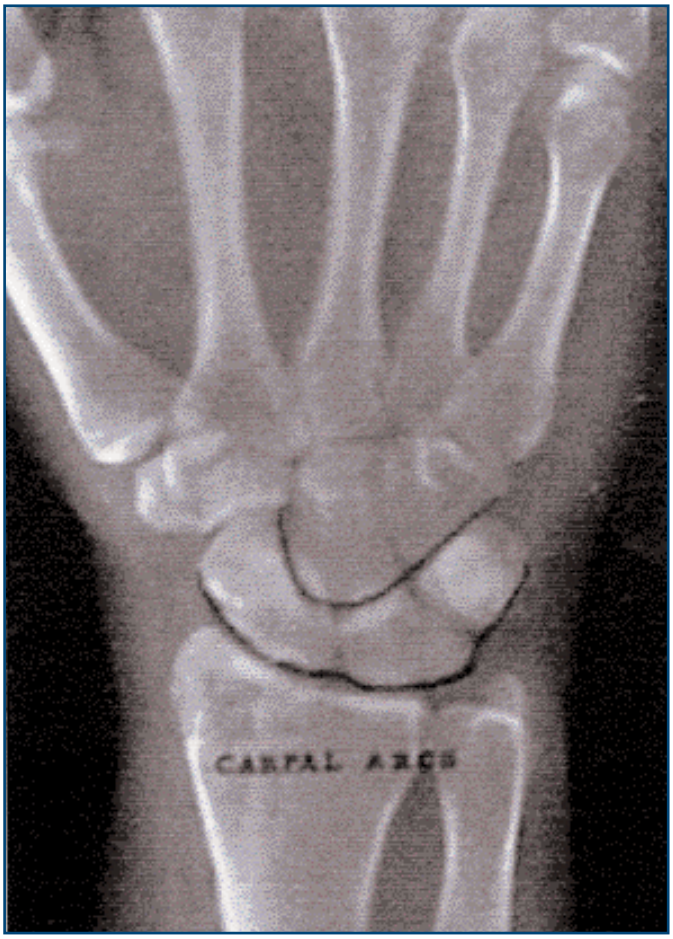

Figure 3. Proximal and distal carpal arcs on the PA radiograph of the wrist. Adapted from reference 3.

ulna variance is defined by the distal articular surface of the ulna, located 2 mm or more distal to the contiguous distal surface of the radius. This is associated with TFCC abnormality and ulnolunate abutment.[3,14] Negative ulna variance occurs when the distal articular surface of the ulna is located 2 mm or more proximal to the contiguous distal surface of the radius; this is associated with increased incidence of Kienbock's disease.[3] It is important for the wrist to be in neutral position when a PA film is taken. Slight supination increases the measurement of negative ulna variance, and pronation decreases the measurement.

Figure 4. Distal radioulnar joint and the scaphoid fat stripe on PA view of the wrist. Adapted from reference 3.

After examining carpal alignment and the DRUJ, the scaphoid fat stripe should be noted (Figure 4). This soft-tissue landmark is displaced with fractures on the radial side of the wrist, including scaphoid fractures.

Lateral view. In this view, the proximal pole of the scaphoid, lunate and triquetrum are superimposed. The radial styloid process is centered over the proximal carpal row and the ulnar head overlaps the distal radius. It is particularly important to pay attention to the relationship between the radius, lunate, capitate, third metacarpal and scaphoid when interpreting this view.

In a normal wrist, a lateral view demonstrates the base of the third metacarpal attached to the distal capitate, and the proximal pole of the capitate cupped in the lunate.[1] The lunate is seen in the lunate fossa of the distal radius.

The relationships between these structures can be evaluated by examining the relationship between their longitudinal axes.

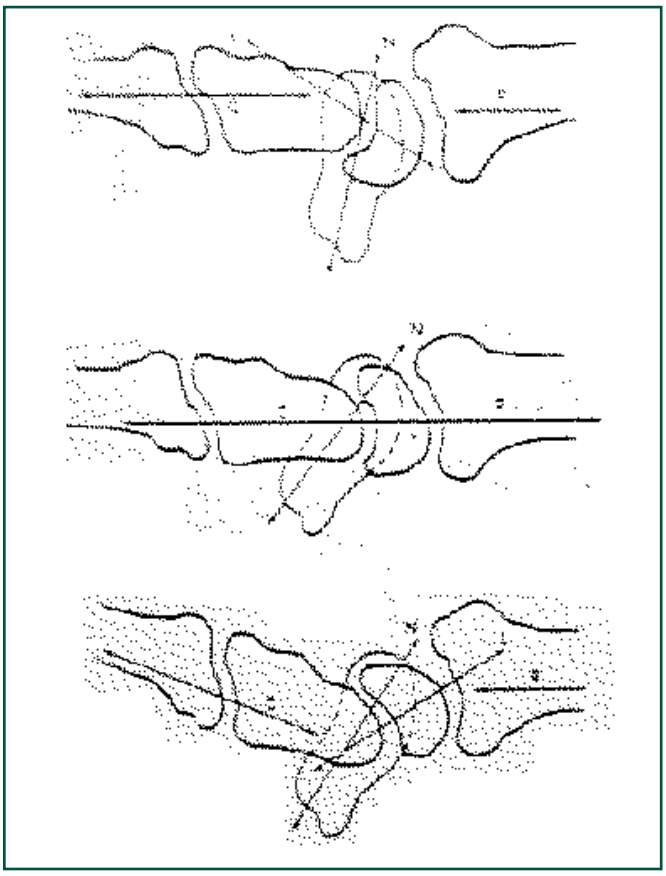

Figure 5. Scapholunate angle on a lateral projection.

R = Radius, N = Navicular (Scaphoid), L = Lunate, C = Capitate

Top. Dorsiflexion instability. The lunate is flexed toward the back of the hand and the scaphoid is displaced vertically. The angle between the two axes is greater than 60 degrees.
Middle. Normal alignment. A continuous line can be drawn through the radius, lunate and capitate; this line then intersects the scaphoid axis at 30 degrees to 60 degrees.
Bottom. Palmar flexion instability. The lunate is flexed toward the palm, and the angle between the two axes is less than 30 degrees.

Adapted from reference 11.

A line drawn parallel to the center of the radial shaft is its axis. The lunate axis is drawn through the midpoint of the lunate perpendicular to a line connecting the anterior and posterior lunate poles. The longitudinal scaphoid axis is drawn by a line connecting the midpoint of its distal articular surface to its proximal articular surface (Figure 5).

The longitudinal axes of the radius, lunate and capitate normally lie within 10 degrees of each other. Flexion or extension can alter the normal angles by 20 degrees in a normal wrist. The scapholunate angle measures 47 degrees (range: 30 degrees to 60 degrees) in normal individuals, and is commonly used to evaluate the midcarpal region.[1,3]

The pronator fat stripe is an important soft-tissue landmark on a lateral view. Normally, it can be visualized 1 cm anterior to the surface of the distal radius. Displacement or obliteration of the fat stripe suggests fractures of the radius.

Oblique views. These views are taken with the wrist placed at 45 degrees between the PA and lateral positions. The external oblique (partial pronation) view is used to examine the scaphoid, trapezoid, trapezium, first metacarpal and associated joints. The internal oblique (partial supination) view provides information on the pisiform, adjacent triquetrum and the joint.[15] Subtle fractures of the radial and ulnar styloid processes are best visualized in oblique views.

Special views. The carpal tunnel view focuses on the palmar aspect of the wrist. It is used to assess any impingement of contents within the carpal tunnel. Any fracture resulting in a loose body trapped within the carpal tunnel can be visualized with this view.

Hyperextension injuries resulting in fracture of the scaphoid tuberosity, trapezium or hook of the hamate often cause impingement within the carpal tunnel.[16,17] The scaphoid view is used to detect scaphoid fractures. This is the most common carpal bone fractured during traumatic wrist injuries, howev-

Table 4

INTERPRETING ROUTINE RADIOGRAPHS OF THE WRIST

Posterior-Anterior View

- Ensure both the proximal and distal arcs formed by the carpal bones are continuous. Discontinuity in the arcs suggests fracture and/or dislocation.
- Look for proper joint space width. Joint space between the carpal bones normally measures 1 mm to 2mm. The distal radioulnar joint space normally measures 2 mm. Increased joint space can indicate fracture/dislocation. Decreased joint space suggests arthritis.
- Look for displacement of the scaphoid fat stripe. Changes in fat stripe position may indicate radial-sided fractures.

Lateral View

- Examine the relationship between the axes of the radius and carpal bones. The scapholunate alignment is a common area to examine, as scapholunate dissociation can result from injury.
- Displacement of the pronator fat stripe greater than 1 cm anterior to the distal radius indicates a fracture through the radius.

Oblique Views

- Look for fractures of the radial and ulnar styloid processes.

Special Views

- Carpal tunnel impingement.
- Scaphoid fracture.
- Notice increased joint space width on stress views. This would suggest ligamentous injuries.

er, it may not be easily identified with routine views. In any acute wrist injury associated with radial-sided wrist pain, a scaphoid view should be obtained.[18] Oblique ulnar views can be used to examine the hamate.

Ligament instability can be assessed with PA films taken in maximal radial and ulnar deviation. Lateral views can be taken in maximum flexion and extension. An additional PA view obtained with a clenched fist (axial loading of the wrist) stresses the ligaments.[3] Injured ligaments may result in abnormal alignment or increased joint space, which can only be seen under stress views.

Table 4 summarizes the important elements to consider when interpreting plain films of the wrist.

Computed Tomography (CT)

In most cases, plain radiographs, in conjunction with the history and wrist examination, are sufficient when diagnosing wrist conditions.

CT, however, can be used to evaluate osseous and articular morphology, as well as pathologic changes (*e.g.*, cysts and tumors).[3]

Although CT may not be necessary in demonstrating fractures, it is effective in evaluating the degree of healing within carpal bones. In comparison to bone scans, CT is advantageous in its ability to define the loca-

tion of a fracture, whereas a bone scan can only indicate the presence of a lesion within a region.

Magnetic Resonance Imaging (MRI)

MRI is used to evaluate soft tissues and vascularity of the carpal bones.

Spin-lattice relaxation time (T1) weighted images provide a higher resolution in evaluating anatomy. Spin-spin relaxation time (T2) weighted images are useful in demonstrating cysts, tumors and fluid. MRI is the most accurate modality (other than biopsy) for assessing the vascularity of the lunate and is more specific than bone scanning in diagnosing Kienbock's disease. MRI is frequently used to diagnose occult scaphoid fractures.[19]

Radionuclide Imaging

Bone scans are sensitive for wrist injuries, however, they are less specific and are more useful as a screening test. Scintigraphy is used to assess the presence of early phases of reflex sympathetic dystrophy—osteonecrosis of the scaphoid, lunate and capitate.[5,16] Occult fractures or pathologic conditions that cause an increase in bone turnover also can be evaluated by radionuclide imaging.

Clinical Features of Common Wrist Disorders

Gaglion Cyst

The ganglion cyst is the most common soft tissue tumor of the wrist. The synovial cyst usually originates as an out-pouching from the synovial joints of the carpus or tendon sheaths.[20, 21] The history often involves the spontaneous occurrence of a painless or minimally symptomatic cystic mass on the dorsal or palmar wrist. The mass may first be noticed following injury or repetitive motion. Ganglia often enlarge or become more symptomatic following activity, reflecting an increase of fluid transfer from the joint into the cyst. On physical exam, the mass appears as a swelling on the middorsal or radiopalmar wrist. There is variable tenderness, ranging from painless to marked tenderness. It is most often cystic, however, the mass may be firm or hard. Palmar flexion of the wrist accentuates the boundaries of the dorsal ganglion, or may reveal an occult ganglion. Similarly, dorsiflexion may accentuate the boundaries of a palmar ganglion. Transillumination with a small light placed against the lesion can readily confirm the diagnosis and establish the extent of the boundaries of the lesion. Superficial lesions that do not transilluminate raise the suspicion of solid masses.

Gout is the most common inflammatory arthropathy in men over 40 years of age.

Gout

Gout is the most common inflammatory arthropathy in men over 40 years of age.[20] This condition results from deposits of monosodium urate crystals within the joint. The onset of gouty arthritis is sudden and dramatic. Typically the patient goes to sleep asymptomatic and is awakened by pain and swelling in the wrist. The wrist may be warm, red, tender and appear cellulitic. The pain may be severe, and even lightly touching the surface may be intolerable. The swelling and inflammation can be intense enough to produce desquamation of the skin over the

wrist.[21] Radiologic features are not normally seen until six to 12 years after the initial attack and are present in 50% of affected patients. Calcifications develop in gouty tophi in 50% of affected patients.[20,21] "Punched-out" bony lucencies may develop secondary to erosion from longstanding soft tissue tophi.

The definitive diagnosis consists of needle aspiration of the acutely inflamed joint. The aspirated fluid should be analyzed for crystals, cell count, Gram stain, and culture. Identification of negatively birefringent needle-shaped crystals (monosodium urate) under a polarizing microscope is diagnostic of gout.

MRI is frequently used to diagnose occult scaphoid fractures.

Pseudogout

Pseudogout results from the deposition of calcium pyrophosphate dihydrate crystals within joints. The wrist is commonly involved and the radiocarpal articulation is most frequently affected.[20] Unlike rheumatoid arthritis, the distal radioulnar and trapezial-metacarpal joints are rarely affected. Acute episodes are characterized by acute pain and inflammation that can resolve without treatment. The clinical presentation may mimic septic arthritis, acute carpal tunnel syndrome (CTS), rheumatoid arthritis, osteoarthritis, or neurogenic arthropathy.[20,21] The two major radiologic features of this disease are calcification and arthropathy. The radiocarpal compartment is most often affected and noticed radiographically.[20] Findings include joint space narrowing, sclerosis and discrete subchondral cysts.

As with gout, the definitive diagnosis of pseudogout requires the demonstration of crystals in aspirated joint fluid. Under polarized light, the crystals show a weak birefringence and positive elongation.

Inflammatory Arthritis Related to Systemic Disease

Acute arthritis of the wrist can present as the initial sign of systemic arthritis. The onset may be abrupt or gradual. Rheumatoid arthritis, connective tissue diseases (systemic lupus erythematosus and scleroderma) and psoriatic arthritis need to be investigated and referred to the appropriate specialist. Initial investigations should determine whether other organ systems are involved. Laboratory tests include a complete blood count, erythrocyte sedimentation rate, rheumatoid factor and anti-nuclear antibodies.[4,5,8]

Tenosynovitis

Wrist pain aggravated by activity is a characteristic feature of tendon sheath inflammation. Palpable synovial swelling often is an associated finding with this condition. The most commonly involved wrist tendons are the abductor pollicis longus and extensor pollicis.[5] Involvement of these tendons, known as DeQuervain's tenosynovitis, causes pain over the radial styloid. There is usually a history of prolonged use of the wrist and hand.

On examination, soft-tissue swelling, palpable thickening of the tendon, or an associated ganglion cyst may be noticed. A positive Finkelstein test is pathognomonic for DeQuervain's tenosynovitis. Abducting the thumb in the palm of the hand, and then passively stretching the closed hand in an ulnar direction, reproduces the pain. The extensor carpi ulnaris tendon also may be affected. Pain is elicited by resistance to extension of the fourth and fifth fingers.[13]

Radiographs are almost always normal, and further investigations are of minimal value.

Kienbock's Disease

This condition is defined as avascular necrosis of the lunate. The etiology is commonly due to trauma in which the blood supply to the lunate is disrupted. Often times, however, the cause is unknown. Kienbock's disease tends to affect younger adults and can present as diffuse wrist pain, or it may be asymptomatic. On X-ray, the lunate appears with increased radio-density due to avascular necrosis and subsequent sclerosis. Relative shortening of the ulna, associated with Kienbock's disease, also can be identified on X-ray.

Peripheral Nerve Entrapment

CTS results from entrapment of the median nerve beneath the carpal ligament at the wrist. The patient usually presents with insidious wrist pain, which radiates to the digits or proximally to the forearm. Associated symptoms include pins-and-needles sensations, weakness and decreased co-ordination. Diminished two-point discrimination is the earliest objective finding. The pattern of sensory involvement involves the palmar side of the thumb and the first and second digits. Diagnosis is based on the history and confirmed by Phalen's and Tinel's tests. Nerve conduction studies are the best method of confirming entrapment of the median nerve, however, these are not used routinely.

Conclusion

Although wrist injuries are not life threatening, they are of great importance in terms of how they can affect daily functioning. Wrist pain can cause significant disability, both acutely and in the long term. The causes of wrist pain vary widely and, without an accurate diagnosis, treatment of wrist pain becomes increasingly difficult. By taking a systematic approach to this problem, consistent and accurate diagnoses can be made. Dx

References

1. Canale ST: *Campbell's Operative Orthopedics.* Mosby, St. Louis, 1998, pp. 3445-51.
2. Hunter JC, Escobedo EM, Wilson AJ, et al: MR imaging of clinically suspected scaphoid fractures. AJR 1997; 168(5):1287-93.
3. Cooney WP, Linscheid RL, Dobyns JH: *The Wrist: Diagnosis and Operative Treatment*. Mosby, St. Louis, 1998, pp. 262-71.
4. Nagle DJ: Evaluation of chronic wrist pain. J Am Acad Orthop Surg 2000; 8:45-55.
5. Wade JP, Bell JG: Wrist pain. Prim Care 1988; 15(4):737-49.
6. Augat P, Hiroyuki I, Jiang Y, et al: Distal radius fractures: Mechanisms of injury and strength prediction by bone mineral assessment. J Orthop Res 1998; 16:629-35.
7. Riley SA: Wrist pain in adult athletes. Postgrad Med 1995; 98(1):147-8, 151-4.
8. Chidgey LK: Chronic wrist pain. Orthop Clin North Am 1992; 23(1):49-64.
9. Appley AG, Soloman L: *Concise System of Orthopedics and Fractures*. Butterworth-Heineman, Cambridge, 1988, pp. 115.
10. Flinkkila T, Raatikainen T, Hamalainen M: AO and Frykman's classifications of Colles' fracture. Acta Orthop Scand 1998; 69(1):77-81.
11. Casey PD, Youngberg R: Scapholunate dissociation: A practical approach for the emergency physician. J Emerg Med 1993; 11:701-7.
12. Reagan DS, Linscheid RL, Dobyns JH: Lunotriquetral sprains. J Hand Surg 1984; 9:502-14.
13. Zelouf DS, Posner MA: Hand and wrist disorders: How to manage pain and improve function. Geriatrics 1995; 50(3):22-6, 29-31.
14. Augat P, Lida H, Jiang Y, et al: Distal radius fractures: Mechanism of injury and strength prediction by bone mineral assessment. J Orthop Res 1998; 16:629-35.
15. Lacey JD, Hodge JC: Pisiform and hamulus fractures: Easily missed wrist fractures diagnosed on a reverse oblique radiograph. J Emerg Med 1998; 16(3):445-52.
16. Kuschner SH, Lane CS: Evaluation of the painful wrist. Am J Orthop 1997; 13(1):17-34.
17. Ko EH, Viegas SF: Chronic wrist pain. Curr Opin Rheumatol 1997; 9:155-8.
18. Tiel-van Buul MMC, van Beek EJR, Broekhuizen AH, et al: Diagnosing scaphoid fractures: Radiographs cannot be used as a gold standard. Injury 1992; 23(2):77-9.
19. Breitenseher MJ, Metz VM, Gilula LA, et al: Radiographically occult scaphoid fractures: Value of MR imaging in detection. Radiology 1997; 203:245-50.
20. Watson KH, Weinzweig, J: *The Wrist*. Lippincott Williams & Wilkins, New York, 2001, pp. 583-589, 684-691.
21. Lichtman DM: *The Wrist and Its Disorders*. W.B. Saunders Company, Philadelphia, 1988, pp. 344-365, 373-375.