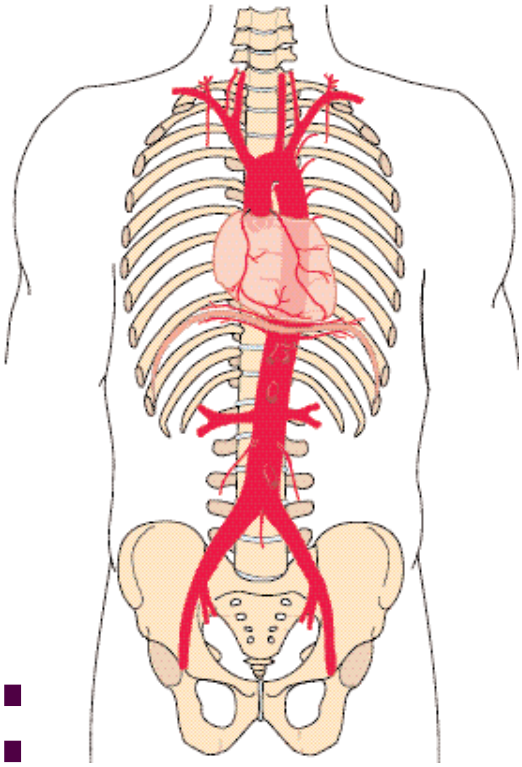

Abdominal Aortic Aneurysms: A New Endovascular Approach

An aneurysm of the abdominal aorta can be treated either surgically or *via* a prosthetic endovascular implant. This article explains what endovascular treatment consists of and outlines its primary advantages and disadvantages.

By Véronique Lapie, MD, FRCS(C)

Dr. Lapie is an assistant professor, department of cardiovascular and thoracic surgery, Centre universitaire de Santé de l'Estrie in Fleurimont, Quebec.

An abdominal aortic aneurysm (AAA) consists of a localized dilation of the aorta, with an increase in diameter of at least 50%.[1] Most AAAs are located in the infrarenal region. Their prevalence has increased 300% in the past 30 years (between 3% and 6% in men over 65 years of age and 10% in men over 70). The increased prevalence of this condition and the aging population have elevated the cost of treating AAAs.

The primary risk associated with the condition is rupture. When this occurs, the resulting global mortality rate is 90%. The risk of rupture is proportionate to the diameter of the aneurysm. It is, therefore, recommended that asymptomatic AAAs exceeding 5 cm, as well as painful or ruptured AAAs, be treated. Open surgery with replacement of the aneurysm by a graft sutured onto a normal segment of the aorta is currently the treatment of choice. The post-operative mortality rate, which is less than 5%, is linked to comorbidity factors, especially cardiac. When such risk factors are present, surgery is contraindicated in approximately 5% of patients. The rate of post-operative complications is between 15% and 30%.

Surgery

The surgical technique first performed by Dubost on March 29, 1951, remains the treatment of choice. The classic procedure involves resecting an aneurysm of the abdominal aorta and replacing it with a prosthesis that is sutured onto healthy vascular segments surrounding the aneurysm. In 41% of AAAs, iliac aneurysms are involved, requiring a repair that extends to the iliac arteries or, in some cases, the femoral arteries.[2] The average increase in diameter of the aneurysm is 4 mm per year. The maximum transverse diameter of the aneurysm is the best indicator of the risk of rupture. The risk of rupture at the five-year point for AAAs of between 4 cm and 5 cm in diameter is 3% to 12%, but ranges from 25% to 41% for AAAs over 5 cm in diameter. The risk of rupture for aneurysms of less than 4 cm is 2% per year.

Summary

Abdominal Aortic Aneurysms: A New Endovascular Approach

Endovascular Treatment

Endovascular treatment consists of a transfemoral implantation of a prosthesis that is held in place by a metallic stent, which provides aneurysm exclusion by means of pressure on the aorta.

Types of Prostheses

Most recent-generation prostheses consist of a graft that is supported along its entire length by a stent made of thermal-shape-memory (TSM) nitinol (an alloy of nickel and titanium). Prostheses can be tubular, digressive or bifurcated, and most are modular.

Patient Selection

The selection of patients is based on precise anatomical criteria which, when followed carefully, can reduce the rate of post-treatment complications. Most study protocols currently include both low- and high-risk patients.

Results

The advantages of endovascular treatment of AAAs in terms of post-operative patient comfort are clear. They include an improvement in pulmonary function and pain management, and less need for intensive care.

Most vascular surgeons currently recommend treatment for AAAs in patients who do not present with comorbidity factors that contraindicate surgery (*i.e.*, all cases of symptomatic or ruptured AAAs and asymptomatic AAAs that are 5 cm or more in diameter). With regard to AAAs 4 cm to 5 cm in diameter, the Ad Hoc Committee on Reporting Standards of the Society for Vascular Surgery and the International Society for Cardiovascular Surgery (SVS/ISCVS) recommend surgical treatment for young patients in good health, as 74% of patients under the age of 69 who are diagnosed with an AAA will eventually undergo surgery anyway.[3,4]

Over the past 40 years, improvements in preoperative preparation, anesthesia and surgical techniques, as well as post-operative care, have reduced the mortality rate associated with non-emergency surgery from 20% to 4%.[5] The rate increases, however, for patients who present with cardiac, pulmonary or renal risk factors, in which case the risk of mortality can be as high 10.5%. The high risk of mortality associated with surgery for a ruptured AAA has remained stable, however, at approximately 50%. Despite technical refinements, non-emergency AAA surgery is still considered a major procedure, with a significant risk of morbidity. According to a multicenter study documented by Johnston, the most frequent complications (15.1%) at the 30-day point are myocardial infarction, arrhythmia and heart failure.[6] The study revealed an 8.4% rate of respiratory failure, 5.4% for renal complications (0.6% of cases requiring dialysis), and 0.6% for ischemic colitis. With respect to vascular complications, there was a 2.3% incidence of post-operative bleeding and a 3.5% incidence of intraoperative limb ischemia. Up to 3.5% of patients are refused treatment because of an excessive risk of morbidity and mortality. Moreover, a history of multiple laparotomies can increase the risk of complications.

Table 1

The Advantages of Endovascular Treatment

Avoidance of

- Laparotomy.
- Tissue dissection.
- General anesthesia.
- Blood loss and transfusions.
- Aortic clamping.

Anticipated Results

- Lower morbidity rate.
- Reduced hospitalization and intensive care.
- Lower costs.
- Increase in number of clinical indications.

Endovascular Treatment

Because of the limitations and risks involved in conventional surgery, research has been conducted to find alternatives. The new developments are not surgical, but rather consist of a noninvasive approach. In 1991, Argentinian surgeon Juan Parodi published the first report on endovascular treatment of an AAA.[7] The treatment consisted of an endovascular transfemoral implantation of a prosthesis held in place by a metallic stent, which provides aneurysm exclusion by means of pressure on the aorta. This technique has since evolved steadily and very rapidly, both in terms of the prosthetic materials and the transfemoral insertion techniques used. General anesthesia, open abdominal surgery and intensive care are, therefore, avoided, and the hospital stay is reduced to three or four days. Normal diet and mobilization are



Figure 1. Vanguard® Prosthesis, Boston Scientific Corporation, Meadox Medicals, Oakland, NJ.

resumed within 24 hours, and the recovery period is merely one to two weeks. These factors are definite advantages in terms of patient comfort (Table 1). The risk of mortality is comparable to that of surgery. This treatment has yielded favorable results so far. It requires long-term follow-up, however, in order to detect the development of endoleaks, which, in most cases, can be treated non-surgically.[8]

Types of Prostheses

Various prostheses, which are remarkably simple and easy to use, are undergoing clinical trials (Figure 1). First-generation prostheses, which are custom-made, are aorto-aortic, aorto-uni-iliac or aorto-unifemoral devices. One of the latter two must be used when an occlusion of the controlateral iliac axis is performed by means of a femoro-femoral bypass using a covered endoprosthesis. Though these types of prostheses can accommodate a larger proportion of patients in terms of anatomical criteria, they are, nevertheless, subject to reduced long-term permeability in femoro-femoral bypasses. A second generation of prostheses was, therefore, developed by French surgeon Dr. Claude Mialhe.[9] These prostheses are produced commercially and have been evolving rapidly and constantly. Most are made of a polyester, polytetrafluoroethylene or polyurethane graft, supported along its entire length by a stent made of thermal-shape-memory (TSM) nitinol (an alloy of nickel and titanium). The prosthesis can be tubular, digressive or bifurcated, and most are modular. The modular concept allows for simple, effective and safe implantation of a bifurcated prosthesis. The two components of the device are a primary aorto-iliac segment and a controlateral iliac arm, which are assembled in the aorta under radiological guidance. Proximal or distal extensions can be added if necessary, allowing for more types of aneurysms to be accommodated.

Patient Selection

The selection of patients is based on precise anatomical criteria which, when followed carefully, can reduce the rate of post-treatment mortality. Patient suitability is determined by an angiography of the aorta and the lower limbs with a graduated catheter, in conjunction with an abdominal scan in which a contrast medium is used in order to obtain a reconstitution at 2 mm intervals (Table 2). The proximal implant site of the prosthesis is examined first (*i.e.*, the proximal neck, defined as the normal portion of the infrarenal aorta). The length must be at least 15 mm and the diameter less than 27 mm, and the vessel must be free of calcification and clots. The implementation site is most often the common iliac arteries, but they must be less than 12 mm.

Angulation must not exceed 120˚ for the proximal neck and 90˚ for the iliac arteries, according to the guidelines issued by the SVS/ISCVS Ad Hoc Committee on Reporting Standards.[7]

For problem-free positioning of the prosthesis (inserted in its deployment device), the diameter of the external iliac arteries must be at least 6 mm. The external diameter that is the threshold for treatment of AAAs remains a controversial topic, with respect to both surgical and endovascular treatment. Most authors agree, however, that either surgical or endovascular treatment should be proposed to patients with an AAA of 5 cm of more. When these anatomical criteria are rigorously applied, approximately 30% of AAAs can benefit from treatment with a modular endoprosthesis.[10] This figure increases to 50% if an aorto-uni-iliac prosthesis is used with a femoro-femoral bypass.[11]

The clinical patient-selection criteria are less clearly defined. In the early 1990s, only patients who could not undergo open surgery were candidates for endovascular treatment. With refinements in the technique and increased experience, however, low-risk candidates for conventional surgery have been treated. Most study protocols currently include both low- and high-risk patients.

Improvements in preoperative preparation, anesthesia and surgical techniques, as well as post-operative care, have reduced the mortality rate of non-emergency surgery from 20% to 4%.

Results

Table 2

Pre- and Perioperative Assessment

Preoperative Assessment

- Classic angiography with graduated catheter
- CAT-scan with contrast medium

Perioperative Assessment

- C-Arm (angiography device)
- Road mapping
- Final angiography for verification purposes

Endovascular treatment of AAAs is a means of avoiding general anesthesia, transperitoneal laparotomy, involving a relatively extensive dissection of the soft tissue, aortic clamping, as well as significant blood loss requiring transfusions and the associated risks.[12] The advantages in terms of post-operative patient comfort are clear. They include an improvement in pulmonary function and pain management, and less need for intensive care.[13] Normal diet and mobilization can be resumed within 24 hours, and the overall hospital stay and convalescence time are significantly reduced. However, the savings in treatment costs are lessened, if not totally cancelled out, by the current cost of commercially produced prostheses and the need for prolonged follow-up with a series of abdominal scans. The intense competition among the various manufacturers should lower the cost of prostheses, therefore, favoring endovascular treatment over conventional surgery. A contrast-enhanced abdominal scan taken before the patient is released from hospital, then at three and six months, allows for adequate follow-up (Table 3). Any anomalies detected by the scan (*i.e.*, leaks or increase in the size of the AAA) can be further

Table 3

Post-operative Follow-up

- CAT-scan with contrast medium.
  - Before patient is released.
  - Three months following procedure.
  - Six months following procedure.
  - Every six months subsequently.
- Aortography if an anomaly is suspected.
- Abdominal X-rays every six months.

investigated by means of an aortography. Endovascular treatment can be carried out at the same time if necessary.

Various authors have reported their short-term and medium-term results (*i.e.*, at six months and two years, respectively). First, the literature reports that the average rate of conversion to open surgery is 3.5%. The mortality rate is comparable to that of conventional surgery—3.2% (2.3% for low-risk patients and 9.8% for patients with significant comorbidity factors).[10] Systemic morbidity, as well as morbidity linked to the prosthetic material and the procedure itself, are in the order of 30%, according to Mialhe and May.[9,14] However, the complication rate diminishes as experience with the procedure is gained. Chuter, for instance, noted a drop from 50% to 15% between two groups of patients treated in two successive periods, even though the second group presented with more comorbidity factors.[15]

The Effectiveness of Endovascular Treatment

A successful procedure is defined as total exclusion of the AAA with total absence of proximal and distal leaks, and no extravasation of the contrast material in the aneurysm sac.[16] The prosthesis must be permeable, without tortuosity or stenosis, or any changes in the downstream end. A review of the primary studies in this area have shown high global success rates (70% to 100%), with an average of 84%, involving 767 patients and follow-up ranging from six months to six years.[17] The causes of failure are multiple: endoleaks, incomplete proximal or distal deployment, inadequate positioning, migration of the prosthesis, microembolisms, or thrombosis of the prosthesis.

Endoleaks, defined as the extravasation of the contrast material in the aneurysm sac, are the primary cause of failure. The rate of occurrence varies greatly in the literature (from 0% to 44%) because of differences among the various studies in terms of patient selection, anatomical selection criteria, degree of experience, diagnostic methods, and likely the type of graft.[8] A taxonomy of endoleaks has been established. Type 1 leaks are those related to the graft itself, whether proximally, distally or transversely; Type II leaks are retrograde leaks that occur by reinjection via the inferior mesenteric artery or the lumbar arteries. They also can be classified according to when they are detected—primary or secondary (six months after treatment or later). Treatment can be conservative (consisting of observation alone), endovascular or surgical. It is recommended that all Type I endoleaks be treated as soon as they are detected, as this type of leak is equivalent to a recurrence of the aneurysm. Type II leaks can be observed initially (for approximately one month), as 60% are resorbed spontaneously. The vast majority of leaks can be successfully treated by endovascular means.

Various authors have reported a reduction in the size of AAAs upon complete exclusion.[18] Harris has noted an average reduction of 7.8 mm at 18 months. He points out, however, that there is an increase in size when an endoleak is present, hence, regular,

long-term follow-up of patients that includes abdominal scans, as well as effective and rapid treatment of endoleaks is important.[10] Since 1995, some cases of post-endoleak AAA ruptures have been reported.

Medium-term follow-up with abdominal scans show neck stability. May *et al.* have noted a 3-mm to 4-mm increase in neck diameter in the first six months, with stabilization by 18 months.[14] They attribute the initial increase in diameter to the force exerted by the expandable balloon device on the neck wall.

Conclusion

The viability of endovascular treatment of AAAs has been clearly demonstrated. This treatment method has certain advantages over conventional surgery with respect to patient comfort and the need for fewer hospital resources. The safety of the procedure has been demonstrated by a mortality rate that is comparable to that of conventional surgery and an identical, if not lower, morbidity rate, which is dropping, thanks to increased experience in the procedure and constant technological improvements. The latter, along with competition among manufacturers of the prostheses, should bring down the cost of endovascular treatment below that of conventional surgery. The short- and medium-term effectiveness of the endovascular approach also has been established. Until the long-term results are known, it is recommended that a controlled environment be adopted with a strict long-term follow-up plan.

This new treatment constitutes the greatest revolution in the treatment of vascular diseases in the past 40 years. It has raised a very favorable response not only within the medical community, but also among patients. Patients must be clearly informed, however, that endovascular treatment is relatively new and is still considered a secondary alternative to conventional surgery.

References

1. Johnstone KW, Rutherford RB, et al: Suggested standards for reporting on arterial aneurysms. J Vasc Surg 1991; 13:452.
2. Brewster DC, Retana A: et al: Angiography in the management of aneurysms of the abdominal aorta. N Engl J Med 1975; 292:822.
3. Hollier LH, Taylor LM, Ochsner J: Recommended indications for operative treatment of abdominal aortic aneurysms. J Vasc Surg 1992; 15:1046.
4. Brown PM, et al: The selective management of small abdominal aortic aneurysms: The Kingston Study. J Vasc Surg 1992; 15:21.
5. Ernst CB: Abdominal aortic aneurysm. N Engl J Med 1993; 328:1167.
6. Johnston KW: Multicenter prospective study of nonruptured abdominal aortic aneurysm. Part II. Variables predicting morbidity and mortality. J Vasc Surg 1989; 9:437.
7. Parodi JC, Palmaz JC, Garone HD: Transfemoral intraluminal graft implementation for abdominal aortic aneurysm. Ann Vasc Surg 1991; 5491-9.
8. Ahn SS, Rutherford RB, Johnstone KW, et al: Reporting standards for infarrenal endovascular abdominal aortic aneurysm repair. J Vasc Surg 1997; 25:405.
9. Harris P: Aneurysms of the abdominal aorta: Results of endoluminal repair. J Cardiovasc Surg 1998; 39:23.
10. Bayle O, Branchereau A, Rosset E, et al: Morphological assessment of abdominal aortic aneurysms by spiral computed tomographic canning. J Vasc Surg 1997; 26:238.
11. D'Ayala M, Hollier LH, Marin ML: Endovascular grafting for abdominal aortic aneurysms. Surg Clin North Am 1998; 78:845.
12. White GH, Yu W, May J, et al: Endoleak as a complication of endoluminal grafting of abdominal aortic aneurysm: Classification, incidence, diagnosis and management. J Endovasc Surg 1997; 4:152.
13. May M, White GH, Yu W, et al: Prospective study of anatomico-pathological changes in abdominal aortic aneurysms following endoluminal repair: Is the aneurysmal process reversed? Eur J Vasc Endovasc Surg 1996; 12:11.
14. White GH, May M, McGahan T, et al: Historic control comparison of outcome for matched groups of patients undergoing endoluminal versus open repair of abdominal aortic aneurysms. J Vasc Surg 1996; 23:201.
15. Boyle JR, Thompson JP, Thompson MM, et al: Improved respiratory function and analgesia control after endovascular AAA repair. J Endovasc Surg 1997; 4:62.
16. Mialhe C, Amicabile C, Becquemein JP: Endovascular treatment of infrarenal abdominal aneurysms by the Stentor system: Preliminary results of 79 cases. J Vasc Surg 1997; 26:199.