


Infantile Perianal Protrusion

Alexander Leung, MBS, FRCPC, FRCP (UK & IreI)

Meet Abigail

- A 9-month-old girl is noted to have an asymptomatic mass protruding from the perianal area. She is the product of an uncomplicated, full-term pregnancy with normal spontaneous delivery.
- Her medical history is unremarkable, except that she has had constipation since she was six-months-of-age when she was started on solid food.
- She has bowel movements once every two to three days. The stools are hard and occasionally blood streaked.
- On examination, there is a pyramidal nontender mass in the perianal area, along the midline, anterior to the anus. The rest of the examination is normal.



What is your diagnosis?

- a) Perianal skin tag c) Hemorrhoid e) Infantile perianal protrusion
b) Genital wart d) Rectal prolapse

Send in your correct answer for a chance to win a **CME** courier pack!

Win



Fill in the information below and fax this page to:

1 (888) 695-8554

If you diagnose correctly, you will be entered in our monthly draw.

Please circle the letter you believe corresponds to the correct answer.

Your Answer: **a** **b** **c** **d** **e**

Name: _____

Address: _____

Tel: _____

E-mail: _____

Or e-mail the answer to **cme@sta.ca** and include "CME courier pack" in the subject line. Also, include your NAME, ADDRESS and PHONE NUMBER.

See page 4 for the answer to last month's case →



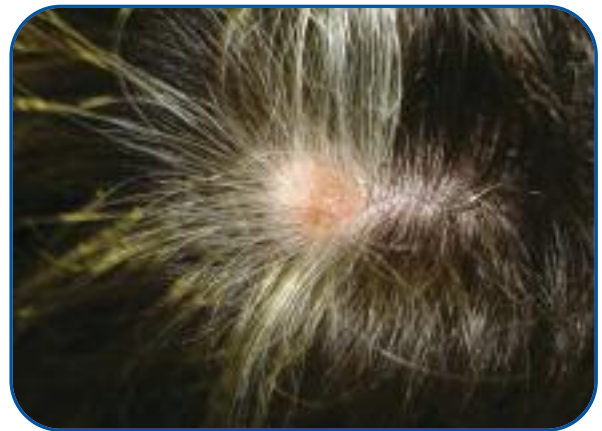Here is the answer to last month's case

Meet Harry

- He is a 20-year-old male who noted a white patch of hair on his scalp six months ago
- He has had a palpable lesion in that area for years

Physical Examination

- There is a visible localized area of gray hair surrounding a speckled, pink nevus



What is your diagnosis?

- | | | |
|---------------|------------------------------|----------------------|
| a) Vitiligo | c) Resolving alopecia areata | e) Familial poliosis |
| b) Halo nevus | d) Melanoma | |

Answer: B

Halo Nevi (**answer b**) are most common in children and young adults. A central nevus is surrounded by an area of hypo-or de-pigmentation. The nevus may be flat, raised, pink, or pigmented. The loss of colour in the surrounding skin occurs over a period of weeks to months. While the most common area is the back, if it occurs on the

scalp, there will be loss of hair pigmentation around the nevus. The basis of the process is poorly understood.

The subsequent course is variable. Usually the central nevus regresses and the surrounding halo repigments (as will the hair), but the central nevus may persist. The process may take years.

Rarely, a similar process occurs around a melanoma, but the hypopigmentation is irregular. This is more likely in individuals older than 40.

cme

Stanley Wine, MD, FRCPC

Congratulations

to our winner for the month of
October 2011!

Dr. Sandy J. Murray
Red Deer, Alberta