

Small Smelly Pits

Benjamin Barankin, MD, FRCPC

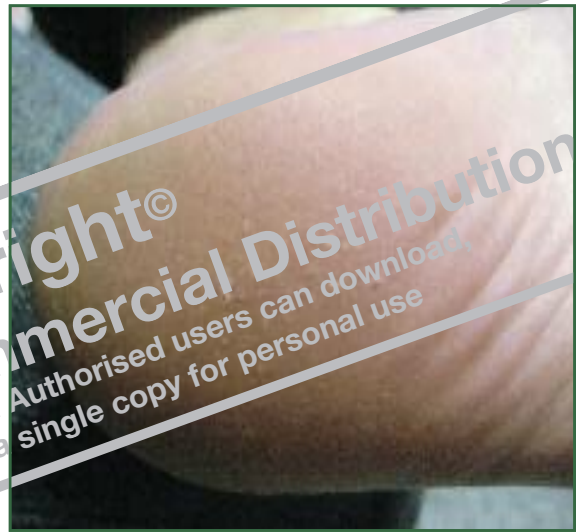
A 33-year-old female presents with small pits on her plantar feet and with a foul odour.

What is your diagnosis?

- a) Tinea pedis
- b) Pitted keratolysis
- c) Hyperhidrosis
- d) Bromhidrosis
- e) Palmoplantar keratoderma

Pitted keratolysis (**answer b**) is a skin disorder characterized by 1-3mm discrete round pits affecting the pressure-bearing aspects of the plantar feet. It is due to a superficial cutaneous bacterial infection, most commonly by *Micrococcus sedentarius*.

Under appropriate conditions (*ie*, prolonged occlusion, heat & humidity, and hyperhidrosis), this bacteria proliferates and produces proteinases that destroy the stratum corneum, creating pits. There is no discomfort although the feet are malodorous. The diagnosis is clinical.



Topical antibiotics such as erythromycin or clindamycin are usually curative. Benzoyl peroxide is also effective.

cme

Dr. Barankin is a Dermatologist practicing in Toronto, Ontario.