

## Rough Split Thumb Nail

Benjamin Barankin, MD, FRCPC

A 44-year-old female presents with a rough, split nail on her thumb. She is bothered by the appearance and is worried about a fungal infection

### What is your diagnosis?

Median nail dystrophy.

This results from a compulsive habit. The person repeatedly traumatizes the proximal nail fold of the thumb, typically using the adjacent index finger. Occasionally this is a bilateral finding. Treatment is difficult as habits are difficult to break. In some cases, patients aren't aware that they are the cause of the nail abnormality. Behaviour modification and stress reduction techniques are advised.

*In some cases, patients aren't aware that they are the cause of the nail abnormality*

Sometimes, breaking the habit can be accomplished by an alternative activity that keeps the fingers busy, such as knitting or needlepoint.


cme

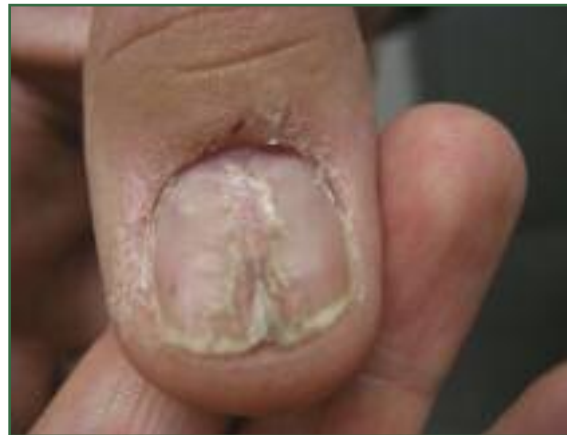

Figure 1. Rough split thumb nail

Dr. Barankin is a Dermatologist practicing in Toronto, Ontario.

Topical gel  
**BenzaClin™**  
Clindamycin, as phosphate,  
1% and benzoyl peroxide 5%  
**Available in  
50 g pump**



BenzaClin™ Topical Gel (clindamycin, as phosphate, 1% and benzoyl peroxide 5%) is indicated for the topical treatment of moderate acne vulgaris characterized by comedones, inflammatory papules/pustules, with or without an occasional cyst or nodule (Grade II to III). BenzaClin™ Topical Gel is not indicated for the treatment of cystic acne (Grade IV).

Product Monograph available upon request or at [www.sanofi-aventis.ca](http://www.sanofi-aventis.ca).

DERMIK®  
the dermatology division of sanofi-aventis Canada Inc.



**sanofi aventis**  
Because health matters