

# Parkinsonian Syndromes

By Guylaine Chiasson, MD, FRCPC; and Michel Dugas, MD, FRCPC

## Case

Mrs. S. is an 81-year-old patient who was admitted to hospital with pneumonia. The case history indicates aspiration pneumonia, peptide-induced stenosis of the esophagus, Type 2 diabetes and depression. The patient presented with parkinsonian syndromes during her hospital stay.

The relevant case history confirms she has had frequent retropulsion falls in the last nine months. Her autonomy is also diminishing, both on the instrumental, or intermediate, activities of daily living (IADL) and activities of daily living (ADL) levels.

The physical examination reveals normal vital signs without any evidence of orthostatic hypotension, Parkinson's facies, less frequent blinking and a widening of the eyelid in a "surprised" look. Vertical optical movement is decreased, especially downward gazes, while horizontal optical movements remain normal. Axial rigidity is obvious.

Deep reflexes are normal and the cutaneous plantar responses are flexed. Some frontal signs are present, affecting the glabella, as well as the jaw and palmate nerves. The patient presents with neither tremors nor cogwheels. The rest of the physical examination is noted as normal. The computerized axial tomography (CAT) scan confirms cortical, subcortical and cerebellar atrophy.



### *Question:*

*What is the diagnosis?*

## Parkinsonian Syndromes

Table 1

### Differential Diagnosis of Parkinson-Plus

	PD	PSP	SDS	SND	OPCA	CBD	ATD-P
Bradykinesia	+	+	+	+	+/-	+	+/-
Rigidity	+	+	+	+	+	+	+/-
Action tremor	+	+	+	+	+	+	+/-
Tremors	+	-	-	-	+/-	+/-	-
Ataxia	-	-	+/-	-	+	-	-
Dysautonomy	+/-	+/-	+	+/-	+/-	-	-
Dementia/ Dysarthria	+/-	+	+/-	-	-	+/-	+
Dysphagia	+/-	+	+/-	+	+	+	+/-
Dystonia	+/-	+/-	-	+/-	-	+	-
Eye Apraxia	-	+	-	+/-	-	+/-	-
Limb Apraxia	-	-	-	-	-	+	+/-
Myoclonus	+/-	-	-	-	-	+	+/-
Neuropathy	-	-	+/-	-	+/-	-	-
Oculomotor tremors	-	+	+/-	-	+	+	+/-
OH	+/-	+/-	+	+/-	+/-	-	-
Night tremors	+/-	+/-	+	+/-	+/-	-	-
Signs asymmetrical	+	-	-	-	-	+	-
Response to L-dopa	+	+/-	+/-	+/-	-	-	-

PD = Parkinson's Disease; PSP = Progressive Supranuclear Palsy; SDS = Shy-Drager Syndrome; SND = Striato-Nigral Degeneration; OPCA = Olivopontocerebellar Atrophy; CBD = Corticobasal Degeneration; ATD-P = Alzheimer-type Dementia with Parkinsonism; Dis. = disorder; OH = Orthostatic Hypotension.

Adapted from Stacy M, Jankovic J: Differential diagnosis of Parkinson's disease and the parkinsonism-plus syndromes. *Neurologic Clinics*; 10(2):341-59.

This clinical case illustrates a parkinsonian syndrome that is not primary Parkinson's disease. It is, in fact, a progressive supranuclear paralysis case. This disease is part of a syndrome that includes variances of clinical elements grouped together under the term "parkinson-plus."

We use the term parkinson-plus to refer to a heterogeneous group of diseases that present as a parkinsonian syndrome (different from primary Parkinson's disease), associated with other neurological symptoms. This disease group represents approximately 15% of consultations referred to specialized neurological clinics. These disorders are often confused with primary Parkinson's disease while their prognosis —



Dr. Chiasson is geriatrician, Hôpital Charles Dumont, Moncton, New Brunswick.



Dr. Dugas is assistant professor, department of medicine, Université Laval, Centre Hospitalier Universitaire de Québec, Ste. Foy, Quebec.

### Summary

### Parkinsonian Syndromes

- Supranuclear palsy is the most frequent cause of parkinson-plus, representing 6% to 12% of parkinsonian cases referred to tertiary centres.
- Multisystem atrophy is a neurodegenerative disease that results in Parkinsonian syndrome with an additional impairment to the autonomic nervous system, pyramidal tract or cerebellum.

as well as their response to medical treatment — differs enormously from that of Parkinson's disease. It is, therefore, important to differentiate them. Several diseases can present themselves with a parkinsonian-like syndrome (Table 1). The term parkinson-plus, however, is reserved for referring to progressive supranuclear palsy (PSP), multisystem atrophies and corticobasal ganglionic degeneration. It is important to note that Lewy body dementia may also present with a parkinsonian syndrome and is sometimes included in the parkinson-plus group, but we will not address this disorder in this article.

### Progressive Supranuclear Palsy

Steele, Richardson and Olszewski described the disease, also known as the Steele-Richardson disease, for the first time in 1964.<sup>1</sup> It is the most frequent cause of parkinson-plus, representing 6% to 12% of parkinsonian cases referred to tertiary centres. It is estimated that the prevalence among the general population is about 1% of that of Parkinson's disease — a prevalence that is probably underestimated in the sub-diagnosis.

The disease usually begins in patients around the age of 60 and affects men more than women

(2:1). The cause remains unknown. It is often sporadic, although some familial cases have been reported recently. Several hypothetical causes were suggested, namely viral infections, toxic exposures and multi-cerebral infarctions, but none of them have been accepted to date.


PSP usually begins insidiously with postural instability, bradykinesia and axial rigidity, which cause patients to fall. Tremors are rare and usually absent.

**Ocular impairments.** Ophthalmoplegia is an important characteristic of this disease. It may be absent at the onset of the disease, making the diagnosis more difficult. The majority of patients, however, invariably experience ocular impairments



AstraZeneca

Can the  
**ratio**  
change the future?

The TC/HDL-C ratio is a **comprehensive lipid assessment** that encompasses the risk associated with both elevated LDL-C **and** reduced HDL-C. It is a key treatment goal in current Canadian Cholesterol Treatment Guidelines.<sup>1</sup>

Are you treating to ratio? 

References: 1. Durrig JJ, Laveie L, Degrassi GR, Cudde G, Lantieri E. HDL-cholesterol as a marker of CVD risk: the Global cardiovascular study. *Atherosclerosis* 2008;182(2):268-73. 2. Fuster J, Fuster JJ, Grewel JJJ Jr., McPherson PP for the Working Group on Hypercholesterolemia and Other Dyslipidemias. Recommendations for the management and treatment of dyslipidemia. *CMAJ* 2003;169(10):1441-7.

The AstraZeneca logo is a trademark of AstraZeneca PLC and is used under license by AstraZeneca Canada Inc.  

# Parkinsonian Syndromes

Table 2

## Characteristics and Criteria Used to Diagnose MSA

### Urinary or Autonomic Impairment

*Urinary and autonomic characteristics:*

- Orthostatic hypotension (lower systolic BP by 20 mmHg or diastolic by 10 mmHg).
- Urinary incontinence or incomplete voiding of the bladder.

*Criteria for urinary or autonomic impairment in multisystem atrophy (MSA):*

- Orthostatic drop of 30 mmHg of systolic tension or 15 mmHg.
- BP urinary diastolic or incontinence (persistent voiding partially or totally involuntarily, with erectile dysfunction in men) or both.

### Parkinsonism

*Features of parkinsonism:*

- Bradykinesia (slowness of motor movements increasing progressively and difficulty in performing repetitive movements).
- Rigidity.
- Postural instability (not caused by primary visual, buccal, cerebellar impairment or proprioception).
- Tremors.

*Criteria for parkinsonism in MSA:*

- Bradykinesia plus at least one item from the *features* listed above.

### Cerebral Impairment

*Characteristics of cerebellar impairment:*

- Gait ataxia (widening of gait with limb and gait ataxia).
- Ataxic dysarthria.
- Limb ataxia.
- Nystagmus induced by the sustained gaze position.

*Criteria for cerebellar impairment in MSA:*

- Gait ataxia plus at least one item from the *characteristics* listed above.

### Corticospinal impairment

*Characteristic of corticospinal impairment:*

- Cutaneous extensor plantars and hyperreflexia

*Criteria of corticospinal impairment with MSA:*

- There was no criteria used to describe MSA.

Adapted from Gilman S, Low PA, Quinn N, et al: Consensus statement on the diagnosis of multiple system atrophy. *J of Neurological Sciences* 1999; 163:94-8.

during the course of the disease.

Vertical gaze palsy, especially of downward optical movements, is a distinctive feature of this disorder. As the disease progresses, horizontal optical movements may be affected, although much less than the vertical optical movements. Because of their impaired downward gaze, these patients are often perceived as awkward when they are eating. This is a type of supranuclear ophthalmoplegia, meaning that the voluntary movements are absent, but the reflex movements of the head are preserved. Patients may present with numerous other ocular impairments, namely failure of convergence and failure of ocular fixation with square-wave jerks, abnormal optokinetic nystagmus, as well as an inadequate suppression of the vertical vestibulo-ocular reflex. Apraxia of eyelid opening or closure may also be present, as well as blepharospasm. Electro-oculogram traces exhibit horizontal hypometric saccadic pursuit movements with normal latency.

**Rigidity.** This typically affects axial movements rather than the limbs, as

observed in Parkinson's disease. Orthostatic hypotension develops, the gait accelerates and patients have difficulty turning, "spinning" rather than taking firm steps, which increases their risk of falling, especially backwards (retropulsion). Parkinsonian syndromes are often symmetrical, which differs from the majority of primary Parkinson's disease cases. Another peculiarity of PSP is cervical and facial dystonia, in particular, retrocollis in the advanced stages of the disease. The face takes on a look that emphasizes wrinkles, rigidity and enlargement of the eyelids. Patients tend to have a "poker-faced" expression.

**Other impairments.** The patient may also present with cortico-bulbar and cortico-spinal impairments with hyperreflexia and Babinski's sign, as well as with a pseudo-bulbar syndrome. Dysphagia and dysarthria are common. Patients' speech is monotonous, spastic and hyper-nasal. They may make sounds involuntarily. There is a higher incidence of dementia – especially in cases of frontal dementia among PSP patients.

**Diagnosis.** The diagnosis for this entity is essentially clinical. Imaging can be somewhat helpful by demonstrating an unspecified, but predominant atrophy of the mid-brain through a CAT scan and magnetic resonance imaging (MRI). Positron emission tomography (PET) scan studies show an impairment of the cortex, as well as frontal hypometabolism. The metabolism of the putamens and caudate nucleus slows down. Non-specified abnormalities are observed on the electroencephalogram.

The neuropathology of this disease is characterized by atrophy of the midbrain. Histology documents neuronal loss and signs of gliosis, granulo-vesicular and neurofibrillary degeneration. The cholinergic neurons of the Meynert ganglions

are affected, as they are with Alzheimer's disease, and a dopamine deficiency in the striatum, substantia nigra and paraolfactive area is observed. It affects the *substantia nigra pars compacta*, as well as the striatum, pallidus, hypothalamus and thalamus.

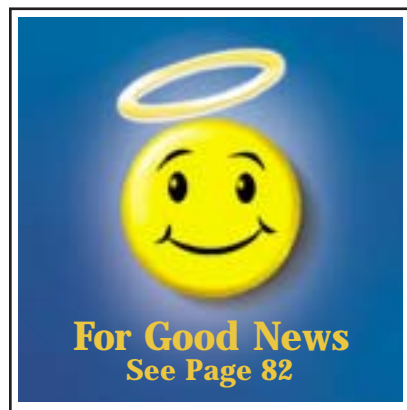**History of disease and treatment.** The survival rate from the onset of the disease is six to 10 years and approximately two years from the time of diagnosis. The ADL is significantly affected, usually following a three- to five-year history. The majority of patients die as a result of immobility and pseudo-bulbar impairments with respiratory complications.

Treatment of this disease is often deceiving. Even if the akinesia improves in some patients with levodopa or dopamine agonists, the improvement is minimal and usually short-term. The majority of patients present with adverse reactions to this drug. It is, nonetheless, recommended that the patient undergo trial treatment with a dopamine agent. Anticholinergics are also ineffective. Several other drugs have

been tried, but they are not very effective and very few, often uncontrolled, studies have been done. Their use is, therefore, speculative. Botulinum toxin can be effective in treating dystonia as well as apraxia of eyelid opening and retrocollis. The success rate of this drug is about 50%. Cholinesterase inhibitors have not been proven to be effective.

## Multisystem Atrophy

Multisystem atrophy (MSA) is a neurodegenerative disease that results in Parkinsonian syndrome with an additional impairment to the autonomic nervous system, pyramidal tract or cerebellum. It is diagnosed when there are impairments noted in





## Parkinsonian Syndromes

two out of the four systems. It is important to point out that the three diseases overlap so often that they have been grouped together. The disease sets in among patients between the ages of 40 and 60 and afflicts both sexes equally. On average, patients survive three to nine years after the onset of symptoms. Neuropathology shows a degeneration of nerve cells in the *substantia nigra pars compacta*, as well as in the *putamen* and *globus pallidus*. More specifically, cytoplasmic oligodendroglial inclusions form as a result of MSA. Neuropathological impairments are similar in the three diseases in the MSA group. Experts held a conference in Minneapolis in 1998 to establish a consensus on the diagnostic criteria of multiple system atrophy (Table 2).<sup>2</sup>

**Treatment of Shy-Drager syndrome is complicated since the drugs used to treat parkinsonism often emphasize orthostatic hypotension.**

### Shy-Drager Syndrome

There is a certain misconception in identifying Shy-Drager syndrome (SDS) in the literature. This term is used interchangeably with the term MSA. Some confusion arises, which may explain contradictory statements, such as whether men are more likely to be afflicted. SDS is diagnosed when impairment of the autonomic nervous system is the most prominent. It is sometimes difficult to distinguish between this disease and Parkinson's disease with impairment of the autonomic nervous system. Impairment is usually more severe and starts earlier with SDS.

**Clinical signs.** Impairment of the autonomic nervous system is usually manifested at the onset

by dysfunction of the genito-sphincter system, as well as impotence, urinary incontinence, micturition urgency and residual post-micturition. The patient then experiences constipation and sometimes stercoraceous incontinence, thermoregulation dysfunctions, a decrease in lacrymal secretions, as well as orthostatic hypotension. The definition of orthostatic hypotension varies in medical literature, but there is consensus that the systolic tension should be lowered to 20 mmHg. When SDS is diagnosed, however, it is necessary to lower it even more to at least 30 mmHg as a diagnostic criterion (Table 2).

Rigidity leads to slowness of movement (bradykinesia) and postural instability. The rigidity is usually bilateral and symmetrical. Signs of cognitive and pyramidal degeneration, as well as muscular and optical atrophy, may also be detected. Patients present with respiratory obstruction and laryngeal stridor, especially towards the end of the disease.

**Diagnosis.** The diagnosis is mostly clinical, but the CAT scan shows atrophy of the brainstem and cerebellum, whereas the MRI indicates hyperintensity of the putamen.

The autonomic nervous system may also be monitored to check for: orthostatic tolerance, cardiac response to various stimuli (getting up, taking deep breaths, *etc.*) and massage of the carotid sinus, serum level of the catecholamines. The patient may also require digestive analysis, using video-fluoroscopy and cutaneous electrogastrography, *etc.*

**History and treatment.** Patients usually present with autonomic signs of the disease when they are in their 50s, while neurological signs appear when they are in their 60s. This disease is predominant among men (2:1). The majority of patients die seven to 10 years after the first symptoms appear, secondarily to strokes, arrhythmia and sleep apnea.

Treatment of the disease is complicated since the drugs used to treat parkinsonism often emphasize

orthostatic hypotension. Non-pharmacological measures should be recommended to patients for the treatment of orthostatic hypotension (diet rich in salt, support stockings and raised headboard). Pharmacological treatment often must be used with fludrocortizone, midodrine and domperidone. As a last resort, octreotide (administered subcutaneously) has been described as effective on a short-term basis for severe cases or post-prandial hypotension. The drug acts as a vasoconstrictor of the venous splanchnologic circulation.

### Olivopontocerebellar Atrophy

Parkinsonism syndromes and cerebellar atrophy characterize olivopontocerebellar atrophy (OPCA). There is neuronal loss in the cerebellum and the brainstem. A variant of this disease is hereditary, but this article will focus on the sporadic type, which is the only parkinson-plus syndrome.

Often difficult to differentiate from the other cerebellar syndromes, parkinsonism needs more research. It usually starts at the brainstem and lower

limbs, followed by difficulty walking. Degeneration of the superior limbs and dysarthria may follow. Patients may present with intention tremors of the inferior limbs. Pyramidal signs may accompany cerebellar evidence.

Electronic imaging shows the characteristic diffused atrophy of the cerebellum and the brainstem, while the pathological studies show a cellular loss in the cerebellum.

**History and treatment.** The age group of patients suffering from OPCA is much more variable than for the other types of parkinson-plus diseases. It generally afflicts patients between the ages of 40 and 60 years, with patients dying within three to nine years after disease onset. There is no effective treatment for this disease, even though some studies report a possible beneficial effect of amantadine on episodes of feeling "stuck in place" when initiating a movement. There is no treatment for cerebellar symptoms, and rigidity does not respond to dopamine treatment. Consequently, the emphasis should be on physiotherapy and ergotherapy treatments.

WWW.DISCOVERYCAMPUS.COM

## The Management of Chronic Obstructive Pulmonary Disease

DiscoveryCampus is an innovative Web site offering high-quality education courses for physicians.

*DiscoveryCampus and Boehringer Ingelheim (Canada) Ltd. are pleased to offer a MAINPRO-M1 accredited course on Management of Chronic Obstructive Pulmonary Disease.*

The course is accredited by:  
The College of Family Physicians of Canada for 2 MAINPRO-M1 credits  
The Canadian Society of Respiratory Therapists  
American College of Chest Physicians. One credit hour in Category 1 of the Physician's Recognition Award of the American Medical Association

To take this complimentary course, go to [www.discoverycampus.com](http://www.discoverycampus.com) and register for RSP 003. Registration is free.

This course is sponsored by an unrestricted grant from



Accreditation details available online.



## Parkinsonian Syndromes

Table 3

### Clinical Signs That Challenge the Diagnosis of Idiopathic Parkinson's Disease

- Instability and severe degeneration
- Quick progression
- Irregular and sudden tremors
- Myoclonia
- Negative response to L-dopa
- Dysautonomy
- Oculomotor disabilities
- Severe dysarthria and dysphonia
- Severe retrocollis or antecollis
- Cerebellar syndrome
- Pyramidal syndrome
- Dementia or cortical cognitive impairment

Adapted from: Fabre N, Brefel-Courbon C, Rascol O: Parkinson Plus. La revue du praticien 1997; 47:1077-82.

### Striatonigral degeneration

**Clinical information.** This disease is the most difficult to differentiate from primary Parkinson's disease. As in Parkinson's disease, the predominant symptoms of striatonigral degeneration involve extra-pyramidal movement. What helps distinguish the two diseases is specific striatonigral degeneration — an absence of tremor, hyperreflexia with cutaneous extensor pulsar responses and pseudo-bulbar degeneration with dysarthria, aphonia and respiratory stridor. The disease progresses quickly. Patients also present with sleep apnea, which is not common in Parkinson's disease. It is also possible to find signs of impairment of the cerebella, although it is quite rare. Ocular impairment may also be observed, as well as square jerks or a mutation in the suppression of oculovestibular reflex.

**Pathologic findings.** The MRI reveals atrophy of the posterior lobe, or even T2 signal abnormalities of the base ganglions. Pathology studies characterize it by a neuronal loss and dark brown pigmentation in the putamen and substantia nigra. Gliosis is found in the striatum. The dopamine levels in the striatum are decreased.

**History of the disease and treatment.** Patients afflicted with this disease survive three to eight years. There is little or no response to levodopa, another clinical sign that helps diagnose the disease. If there is a response, it is very short-acting. Trials for a nasal continuous positive air pressure breathing apparatus (CPAP) for nocturnal inspiratory stridor can be expected. Performing a tracheostomy is the last alternative solution.

### Corticobasal degeneration

Described in 1967 to 1968 by Rebeiz and his colleagues, this disease is a more rare form of parkinson-plus.<sup>3</sup> It begins insidiously when patients are in their 60s. They die within a five- to 10-year period. The disease was first reported to be predominant among men, although subsequent studies did not prove this pattern.

**Presentation.** The main distinction of the disease is its asymmetrical clinical presentation. Symptoms start on an upper limb and stay limited to that area for two to five years before they become generalized. It was originally thought that the symptoms appeared on the left side first, but this notion has since been discarded.<sup>3</sup>

A slowdown and clumsiness of the affected limb, sometimes associated with action tremor, usually mark the onset of the disease. The patient presents with prominent postural instability in the early stages. Cortical disorders and apraxia later set in. The classic feature is the "alien limb phenomenon," where the patient has no control over the jerky, involuntary movements of the limb. One



## Parkinsonian Syndromes

case described, for example, how a patient would fumble through a purse or grab the examining physician's arm. The patient may eventually experience rigidity and dystonia of the hand, which becomes totally non-functional and spastic. The early action tremor can also progress into myoclonus. Apraxia is typical of this disease.

Sensorial signs, such as paresthesia and hypoesthesia, are common at the onset of the disease.

Gait impairments are another common sign at the beginning. Patients move slowly, develop imbalance and gait apraxia. Ocular movements may be affected towards the end of the disease. The vertical gaze may be affected as much as the horizontal gaze. Apraxia of the eyelid opening is also a possible sign of this disease.

The patient may present with pyramidal impairment and hyperreflexia, as well as dysarthria and dysphagia. Cognitive functions usually remain intact during the course of the disease, except for apraxia and impairment of visuospatial and constructive functions. A table regarding dementia associated with this disease has not been established yet. Some authors have tried to compile a draft of the diagnostic criteria.

**Investigation.** Imaging usually reveals an asymmetrical atrophy that involves the frontotemporal contralateral area of the afflicted limb. A PET scan shows this cerebral asymmetrical dysfunction. The electroencephalogram (EEG) is normal at the onset of the disease. Non-specific abnormalities slowly develop in the area of the brain that corresponds to the side that is mainly affected.

Pathology studies reveal neuronal loss with gliosis in the substantia *nigra pars compacta*, as well as the presence of tau-positive glials.<sup>3</sup> Cortical impairment is often dispersed, which is why biopsies of the brain are usually negative.

**Treatment.** Pharmacological treatment is still ineffective. Non-pharmacological methods and interdisciplinary approaches should be used. Patients deteriorate progressively and become bedridden, usually dying from infectious complications, such as aspiration pneumonia.

### Food for thought

As we have already mentioned, it is sometimes difficult to diagnose these diseases, but there are some signs, although sometimes subtle, that may lead us to believe it is not "classical" Parkinson's disease. Tremors that occur when the patient is resting are often absent or irregular, rapid and mixed. Rigidity and slow movements are usually bilateral, except in the case of corticobasal



Nexium is indicated for the treatment of conditions where a reduction of gastric acid secretion is required. Please consult the Product Monograph for patient selection, precautions and warnings.

Nexium is a trademark of AstraZeneca AB, used under license by AstraZeneca Canada Inc.  
The AstraZeneca logo is a trademark of AstraZeneca PLC, used under license by AstraZeneca Canada Inc.

AstraZeneca

555.1.4330 PAB F&D

## Parkinsonian Syndromes

degeneration. Patients lose their balance (ataxia) and fall as a result of the walking and postural disturbances that afflict them early on in the disease. Impairment of other nervous systems (e.g., autonomic, pyramidal and cerebellar systems) are also helpful in diagnosing parkinson-plus. Ocular impairments are very important in the differential diagnosis, as well. These diseases usually progress very quickly and do not respond at all, or very minimally, to dopaminergic treatment (Table 3).

### Conclusion

Idiopathic Parkinson's disease presents a vast array of differential diagnoses. The parkinson-plus group of diseases is an important component. This group of diseases is often not diagnosed because of its heterogeneity, its subtle clinical signs and the failure to recognize it. Nonetheless, it is important to differentiate these diseases not only for research purposes and therapeutic choices, but also for patient diagnosis. Given the quick progression of the disease and how quickly patients lose their mobility and become bedridden, they should be treated quickly by an interdisciplinary team. [CME](#)

#### References

- Cardoso F, Jankovic J: Progressive supranuclear palsy. In: Donald B, Cabre DM (eds.): *Neurodegenerative Diseases*, W.B. Saunders, Philadelphia 1994, pp. 769-83.
- Gilman S, Low PA, Quinn N, et al: Consensus statement on the diagnosis of multiple system atrophy. *J of Neurological Sciences* 1999; 163:94-8.
- Özsancak C, Auzou P, Hannequin D: La dégénérescence corticobasale. *Revue Neurologique (Paris)* 1999; 155(12):1007-20.
- Iranzo A, Santamaria J, Tolosa E: Continuous positive air pressure eliminates nocturnal stridor in multiple system atrophy. *Lancet* 2000; 356:1329-30.
- Lamarre-Cliche M, Cusson J: Octreotide for orthostatic hypotension. *Can J Clin Pharmacol* 1999; 6(4):213-15.
- Pahwa R: Progressive supranuclear palsy. *Medical Clinics of North America* 1999; 83(2):369-77.
- Piccione F, Mancini E, Tonin P, et al: Botulinum toxin treatment of Apraxia of eyelid opening in progressive supranuclear palsy: Report of two cases. *Arch Phys Med Rehab* 1997; 78:525-9.
- Rehman HU: Progressive supranuclear palsy. *Postgrad Med J* 2000; 76:333-336.
- Rojo A, Pernaute RS, Fontán A, et al: Clinical genetics of familial progressive supranuclear palsy. *Brain* 1999; 122:1233-45.
- Siemers E: Multiple system atrophy. *Medical Clinics of North America* 1999; 83(2):381-92.
- Cohen S, Freedman M: Cognitive and behavioural changes in the parkinson-plus syndromes. *Advances in Neurology* 1995; 65:139-57.
- Fabre N, Brefel-Courbon C, Rascol O: Parkinson Plus. *La revue du praticien* 1997; 47:1077-82.
- Jankovic J: Parkinsonism-plus syndromes. *Movement Disorders* 1989; 4(suppl.1):S95-S119.
- Kompoliti K, Goetz CG, Litvan I, et al: Pharmacological therapy in progressive supranuclear palsy. *Archives of Neurology* 1998; 55:1099-1102.
- Lang AE, Riley DE, Bergeron C: Cortical-basal ganglionic degeneration. In: Donald B, Cabre DM (eds.): *Neurodegenerative Diseases*, W.B. Saunders, Philadelphia 1994, pp. 877-93.
- Litvan I, Agid Y, Calne D, et al: Clinical research criteria for the diagnosis of progressive supranuclear palsy (Steele-Richardson-Olszewski syndrome): Report of the NINDS-SPSP International workshop. *Neurology* 1996; 47:1-7.
- Mathias CJ, Williams AC: The Shy-Drager syndrome (and multiple system atrophy) In: Donald B, Cabre DM (eds.): *Neurodegenerative Diseases*, W.B. Saunders, Philadelphia, 1994, pp. 743-65.
- Stacy M, Jankovic J: Differential diagnosis of Parkinson's disease and the parkinsonism-plus syndromes. *Neurologic Clinics*;1992, 10(2):341-59.

#### Suggested Readings

- Ahlskog JE: Diagnosis and differential diagnosis of Parkinson's disease and Parkinsonism. *Parkinsonism and Related Disorders* 2000; 7:63-70.
- Botez MI, Botez-Marquard T, Elie R, et al: Amantadine hydrochloride treatment in olivopontocerebellar atrophy: A long-term follow-up study. *European Neurology* 1999; 41:212-15.